

## Supernumerary Peronei in the Leg Musculature- Utility for Reconstruction

Vandana Mehta, MS; RK Suri, MS; Jyoti Arora, MS; Vandana Dave, MS;  
Gayatri Rath, MS

Muscular variations in the lower extremity are frequently encountered when performing cadaveric dissections. The utility of supernumerary muscles assumes importance in reparative foot surgery. The purpose of the current case study is to report the unilateral presence of double peroneal muscles in the evertors of the foot. The peroneal compartment of an adult Indian male cadaver was dissected during a demonstration class for medical undergraduates. Two bellies of the peroneal longus and brevis muscles were observed. The peroneus longus split into two bellies, superficial and deep, while the brevis displayed superficial/lateral and deep/medial bellies. These additional bellies gained attachment to the lateral calcaneal surface. Disorders of the peroneal tendons provide a basis for lateral ankle pain and instability. Anatomical variants have been associated with lateral ankle diseases. Magnetic resonance imaging can demonstrate these soft tissue variants, and detailed information on the anatomy of the crural region enables a surgeon to plan an operation. This study shows duplication of the peroneal muscle, which may have an impact on reconstructive surgery. (*Chang Gung Med J 2011;34(6 Suppl):62-5*)

**Key words:** supernumerary, peroneal muscles, lateral, ankle

Macalister has described various deviations of the peroneus longus (PL) muscle.<sup>(1)</sup> Among these are its insertions by three tendons into the first, third and fifth metatarsal bones, a slip to the fifth metatarsal behind the brevis and a slip to the lateral malleolus. Only two anomalies of the peroneus brevis (PB) muscle were reported by Macalister, one being a slip to the PL and the other to the abductor digiti minimi. Macalister also described the peroneus digiti quinti as a completely separate muscle arising from the lower fourth of the fibula under the PB in the groove in which its tendon runs, which is inserted into the extensor aponeurosis on the upper surface of the little toe.<sup>(1)</sup> A chief function of the peroneal muscles is to provide the eversion movement essen-

tial to balance the opposing inversion movement.<sup>(2)</sup> Recently, longitudinal tears or attrition of the peroneus brevis tendon (PBT) has been stated as a cause of lateral ankle pain. The combination of the PBT tears and chronic ankle instability has also received notice. Some researchers have reported that this lesion is found in as many as 37% of cadaveric specimens. There is a substantial risk of delayed or missed diagnosis of PBT tears.<sup>(3)</sup> Magnetic resonance (MRI) or ultrasound imaging is recommended to increase the diagnostic accuracy in these patients. Ultrasonography has been suggested as an effectual means to establish the diagnosis of longitudinal tears of the PL tendon and PBT. Tendon size, shape, location, and integrity, as well as associated anatomic

---

From the Department of Anatomy, Vardhaman Mahavir Medical College & Safdarjung Hospital, New Delhi, India.

Received: Sep. 28, 2011; Accepted: Nov. 24, 2011

Correspondence to: Dr. Vandana Mehta, Department of Anatomy, Vardhaman Mahavir Medical College & Safdarjung Hospital, New Delhi, India. Tel: 91-9910061399; Fax: 011-25927323; E-mail: drvandanamehta@gmail.com

abnormalities and variants, can be appraised with ultrasonography.<sup>(4)</sup> The current report describes the unusual presence of double peroneal muscles, which to the best of our knowledge has not been elucidated in the anatomical literature. These duplicated peroneal bellies and tendons may be demonstrated accurately with ultrasonography prior to surgical intervention in this area. Furthermore, reconstructive surgeons need to take these supernumerary muscles into consideration when doing reparative procedures on the foot.

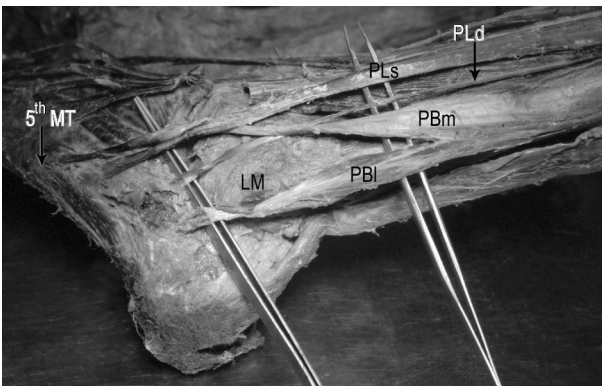
## CASE REPORT

A routine anatomy dissection class revealed unilateral presence of double peroneal muscles on the left leg of an adult male cadaver (Figure). This was discovered for the first time after reviewing 100 lower limbs. The PL had a normal origin from the upper part of the lateral surface of the fibula. It subsequently divided into a larger superficial part and a smaller deep part. The point of division of the PL into its two bellies was 22.1 cm proximal from the tip of the lateral malleolus. The superficial part remained muscular and tendinous above the lateral malleolus and inserted in the normal way into the lateral aspect of the first metatarsal head. The deeper, smaller part of the PL became tendinous after a small 8.6 cm long muscular belly and inserted into the lateral surface of the calcaneum just below the lateral malleolus. The PB muscle originated from the lateral

surface of the fibula as usual. It divided into two bellies 8.2 cm proximal to the tip of the lateral malleolus. One part was superficial and lateral, and the other was deep and medial. The superficial/lateral part became tendinous just above the lateral malleolus and inserted as usual into the base of the fifth metatarsal bone. The deeper medial part of the PB gained distal attachment to the lateral surface of the calcaneum 1.4 cm below the tip of the lateral malleolus. The distance between the insertion of the deeper parts of the PL and PB was 1.4 cm. Innervation to both extra bellies was derived from the superficial peroneal nerve. The remaining musculature and neurovascular structures showed no departure from the normal morphology.

## DISCUSSION

We found no previous report of two supernumerary peroneal muscles in which one of the muscles took origin between the two peronei and the other from beneath the PB. They inserted onto the peroneal trochlea of the os calcaneum and dorsal digital expansion of the fifth toe respectively.<sup>(5)</sup> A comparable case reported two different tendons arising from a single muscle instead of the PL and PB. The smaller tendon which was the PB analogue inserted at the base of fifth metatarsal and the larger tendon which represented the PL analogue to the base of first metatarsal bone. The peroneus quartus also originated from the same belly. That patient had operative exploration because of retromalleolar pain.<sup>(6)</sup> Another study reported two supernumerary peroneal muscles bilaterally during a routine cadaveric dissection. The peroneus quartus muscle originated from the distal part of the fibula and the tendon of the PB, and attached to the peroneal trochlea of the calcaneum whereas the peroneus digiti quinti muscle originated as a small slip from the tendon of the PB, around the malleolus, attaching to the dorsal aponeurosis of the fifth digit. Furthermore, a small separate slip was observed to gain attachment to the fifth metatarsal base.<sup>(7)</sup> Another report showed an unusual tripartite insertion of the PL unilaterally. In addition to the usual insertion onto the base of the first metatarsal bone, two additional slips gained attachment to the first dorsal interosseus and the plantar aspect of the first metatarsal bone. Therefore the first metatarsal bone received two slips of inser-



**Figure** Photograph of the left crural region. Abbreviations used: LM: lateral malleolus; PLs: superficial belly of the peroneus longus; PLd: deep belly of the peroneus longus; PBm: medial belly of the peroneus brevis; PBl: lateral belly of the peroneus brevis; 5<sup>th</sup> MT: fifth metatarsal bone.

tion from the PL.<sup>(8)</sup> The current study reports supernumerary peroneal muscles from both the PL and PB gaining attachment to the lateral calcaneal surface.

A bifid PB muscle leading to chronic subluxation of the peroneal tendons has been described.<sup>(9)</sup> Another MRI study confirmed that tears in the PB tendon may result from anomalous distal attachment of the PB.<sup>(10)</sup> The distally pedicled PB muscle has been established as a viable local flap substitute. The PB was successfully transposed onto the distal third of the leg for coverage of defects. Since the PL was preserved, there was no loss of eversion function and no postoperative complications were recorded.<sup>(11)</sup> A longitudinal vertical splitting of the PB muscle was developed as a new technique to provide adequate coverage of pretibial region defects. This was done principally to avert any loss of function.<sup>(12)</sup> We suggest that with a double PB muscle, one muscle may be safely transposed for such reconstructive maneuvers without jeopardizing function. These anomalies may therefore be taken into account by orthopedic surgeons when contemplating reconstruction in the distal leg region. Transfer of the flexor digitorum longus for posterior tibial tendon insufficiency is routine. Occasionally, this muscle may be particularly small or may have been previously used for transfer. In this event, the PB muscle may be effectively utilized for restoration of balance of the foot.<sup>(13)</sup> The imprecise pathogenesis of longitudinal peroneal tendon tears has led scientists to explore the reasons behind lateral ankle pain and instability. The PB tendon is subject to friction as it lies in a retrofibular position, and coupled with ankle trauma may result in lateral ankle instability and incompetency of the superior peroneal retinaculum. Finally all the above mentioned events may exacerbate recurrent subluxation of the peroneal tendons.<sup>(14)</sup> Longitudinal tears of the PB tendon may lead to symptoms ranging from mild pain to lateral ankle instability. Although the exact pathophysiology is not clearly revealed, reasons which may cause this condition include superior peroneal retinaculum tears, avascular zones in the PB tendon, degenerative processes and abrasion over the calcaneofibular ligaments.

The anatomical reasons for PB tears include a shallow fibular groove, a distally located muscle belly of the PB, an anomalous low-lying peroneus muscle belly and anomalous peroneus quartus and peroneus tertius tendons.<sup>(15)</sup> We hypothesize that the

incidence of double anomalous peroneal bellies could possibly have a bearing on the pathogenesis of chronic ankle instability leading to lateral ankle pain. This could be a result of altering the ankle motion mechanism. It has been established that MRI is the best modality to categorize PB and PL degeneration, hypertrophy, and anomalous muscle bellies and accessory muscles such as the peroneus quartus.<sup>(16)</sup> Peroneal tendoscopy has emerged as an alternative procedure for diagnosing peroneal tendon pathology when MRI fails to identify peroneus quartus and PB anomalies.<sup>(17)</sup> Cavus foot surgery requires lengthening of the PL tendon as it influences all three components of the idiopathic cavus foot which can be accounted for by increased strength and activity of the peroneus muscle, namely varus heel, increased arch height and forefoot adduction.<sup>(18)</sup> The basis for lateral ankle pain and instability is frequently disregarded and is related to disorders pertaining to the peroneal tendons. Anatomical variants have been associated with lateral ankle diseases. MRI imaging aids in diagnosing these soft tissue variants and detailed information on the anatomy of the crural region enables the surgeon to plan an operation. In one MRI study, a bifurcated pattern of the PB was seen.<sup>(16)</sup> Our study showed a duplicated peroneal muscle which may have an impact on reconstructive surgery. Experiments using PL tendon allografts for anterior cruciate ligament (ACL) reconstruction have been performed.<sup>(19)</sup> Clinicians asserted that since the PL tendon is as strong as the ACL, it may act as a replacement for it.

### Conclusions

This study reports double peroneal muscles which would be important for reconstructive foot surgeons attempting to repair this area. Morphological variations of these muscles may be demonstrated by procedures such as ultrasound, MRI, and tendoscopy.

### REFERENCES

1. Macalister A. Observation on muscular anomalies in the human anatomy. Third series with a catalogue of the principal muscular variations hitherto published. *Trans Roy Irish Acad* 1875;25:1.
2. Otis JC, Deland JT, Lee S, Gordon J. Peroneus brevis is a more effective evertor than peroneus longus. *Foot Ankle*

- Int 2004;25:242-6.
3. Karlsson J, Wiger P. Longitudinal split of the peroneus brevis tendon and lateral ankle instability: treatment of concomitant lesions. *J Athl Train* 2002;37:463-6.
  4. Diaz GC, Holsbeeck MV, Jacobson JA. Longitudinal split of the peroneus longus and peroneus brevis tendons with disruption of the superior peroneal retinaculum. *J Ultrasound Med* 1998;17:525-9.
  5. Reimann R. Vier Musculi peronei in einem menschlichen Unterschenkel. *Anat Anz* 1979;145:205-7.
  6. Kim DH, Berkowitz MJ. Congenital variation of peroneus longus brevis muscle -tendon units in association with peroneus quartus: a case report. *Foot Ankle Int* 2006;27:847-8.
  7. Sönmez M, Koşar İ, İmen M. The supernumerary peroneal muscles: case report and review of the literature. *Foot Ankle Surg* 2000;6:125-9.
  8. Jayakumari S, Suri RK, Rath G Arora J. Accessory tendon and tripartite insertion pattern of fibularis longus muscle. A case report. *Int J Morphol* 2006;24:633-6.
  9. Hammerschlag WA, Goldner JL. Chronic peroneal tendon subluxation produced by an anomalous peroneus brevis: case report and literature review. *Foot Ankle* 1989;10:45-7.
  10. Freccero DM, Berkowitz MJ. The relationship between tears of the peroneus brevis tendon and the distal extent of its muscle belly: an MRI study. *Foot Ankle Int* 2006;27:236-9.
  11. Lorenzetti F, Lazzeri D, Bonini L, Giannotti G, Piolanti N, Lisanti M, Pantaloni M. Distally based peroneus brevis muscle flap in reconstructive surgery of the lower leg: postoperative ankle function and stability evaluation. *J Plast Reconstr Aesthet Surg* 2009;63:1523-33.
  12. El-Khatib HA. The split peroneus flap: a new flap for lower leg defects. *J Plast Reconstr Aesthet Surg* 2007;60:898-903.
  13. Song SJ, Deland JT. Outcome following addition of peroneus brevis tendon transfer to treatment of posterior tibial tendon insufficiency. *Foot Ankle Int* 2001;22:301-4.
  14. Saxena A, Pham B. Longitudinal peroneal tendon tears. *J Foot Ankle Surg* 1997;36:173-9.
  15. Taser F, Shafiq Q, Toker S. Coexistence of anomalous m. peroneus tertius and longitudinal tear in the m. peroneus brevis tendon. *Eklemler Hastalik Cerrahisi* 2009;20:165-8.
  16. Wang XT, Rosenberg ZS, Meclin MB, Schweitzer ME. Normal variants and diseases of the peroneal tendons and superior peroneal retinaculum: MR imaging features. *Radiographics* 2005;25:587-602.
  17. Panchbhavia VK, Trevinob SG. Peroneal tendoscopy and report on anomalies diagnosed. *Foot Ankle Surg* 2003;9:131-5.
  18. Smith ST, Weil LS. Peroneus longus tendon lengthening as an adjuvant measure in cavus foot surgery. *J Foot Surg* 1976;15:51-4.
  19. Kerimoglu S, Aynacı O, Saracoğlu M, Aydın H, Turhan AU. Anterior cruciate ligament reconstruction with the peroneus longus tendon. *Acta Orthop Traumatol Turc* 2008;42:38-43.