

Comparison of Directional Coronary Atherectomy-Based Intervention and Stenting Alone in Ostial Lesions of the Left Anterior Descending Artery

Chang-Min Chung, MD; Shigeru Nakamura¹, MD; Osamu Katoh¹, MD

Background: Balloon angioplasty yields suboptimal results and increases the rate of restenosis in the ostium of the left anterior descending coronary artery (LAD). Several non-balloon devices have been used to improve the outcome of dilatation of such lesions.

Methods: This investigation retrospectively compared the results of a directional atherectomy (DCA)-based intervention and stenting alone on the ostial lesions of the LAD, and the effect on the left circumflex artery (LCX) ostium. Sixty-five patients with a successful angioplasty of LAD ostial lesions were studied. Patients were divided into 2 groups: group I (DCA, n = 34) and group II (stenting, n = 31).

Results: After intervention and at the 3-month follow-up, group I exhibited a larger minimal lumen diameter (MLD), smaller-diameter stenosis, and a lower loss index than group II. At 6 months, group I showed a lower cumulative restenosis rate of 32% as compared to 48% for group II ($p = 0.04$). In group I, the MLD of the LCX ostium had not changed after DCA or at follow-up. In contrast, the MLD of the LCX was significantly reduced with stenting alone and during follow-up ($p < 0.01$). The strategy of optimal debulking plus stenting exhibited a restenosis rate of 9%, in contrast to 33% in the optimal debulking alone strategy ($p = 0.05$) after 3 months.

Conclusions: During the intervention for LAD ostial lesions, the DCA-based strategy seemed to be superior compared to stenting alone both in terms of acute and late target lesion revascularization and in terms of the risk of plaque shifting. The best results however were obtained when optimal DCA was combined with stenting.

(*Chang Gung Med J* 2005;28:689-98)

Key words: directional coronary atherectomy, stenting, ostium.

Balloon angioplasty (PTCA) is used to treat ostial stenosis of the left anterior descending artery (LAD) and has been associated with low procedural success rates, a high risk of serious complications,⁽¹⁾ suboptimal dilatation owing to elastic recoil,^(2,3) and a

high rate of restenosis.^(4,5) The development of ablative technologies and intracoronary stents has significantly affected the outcomes of percutaneous interventions for LAD ostial lesions. Notably, coronary stenting leads to less restenosis in focal de novo

From the Department of Cardiology, Chang Gung Memorial Hospital, Chiayi; ¹Cardiovascular Center, Kyoto Katsura Hospital, Kyoto, Japan.

Received: May. 18, 2005; Accepted: Aug. 16, 2005

Correspondence to: Dr. Chang-Min Chung, MD, 6 West Sec, Chai-Pu Road, Pu-Tzi City, Chaiyi Hsien, Taiwan 613, R.O.C. Tel.: 886-5-3621000; Fax: 886-5-3622005; E-mail: cmchung02@hotmail.com

lesions than does balloon angioplasty.⁽⁶⁾ However, restenosis is still a problem in LAD ostial lesions.⁽⁷⁾ Recently, the use of a drug-eluting stent (DES), either a sirolimus-eluting stent (SES; Cypher, Cordis, Johnson and Johnson) or a paclitaxel-eluting stent (PES; Taxus, Boston Scientific), has been associated with lower restenosis rates.⁽⁸⁻¹²⁾ No data are available on the use of DES in LAD ostial lesions.

Directional coronary atherectomy (DCA) with optimal atherectomy yielded a lower restenosis rate than balloon angioplasty.⁽¹³⁾ Treating ostial lesions of the LAD may, however, induce narrowing of the left circumflex (LCX) ostium due to plaque shift or dissection.⁽¹⁴⁻¹⁶⁾ In this investigation, we attempted to assess and compare the acute and follow-up results of stenting alone with those of a DCA-based intervention in treating LAD ostial lesions of native coronary arteries. The effects on the LCX ostial diameter were also determined.

METHODS

Study population

The study group included patients who had undergone a coronary intervention to treat LAD ostial lesions between January 1998 and August 2002. LAD ostial stenosis was defined as a lesion with $\geq 70\%$ diameter stenosis involving the LAD ostium within 0.3 cm of the left main trunk. Patients were recruited if they met all of the following criteria: (1) a reference diameter of ≥ 2.75 mm and a diameter of stenosis of $\geq 70\%$ (a visual estimate); (2) the absence of myocardial infarction (MI) within 1 week; and (3) clinical or functional evidence of ischemia. Angiographic follow-up was performed at 3 and 6 months. Angioplasties were performed if restenosis ($\geq 50\%$ diameter stenosis of the treated site) was observed at the 3-month follow-up. There were 80 LAD ostial lesions treated by all methods, including cutting balloon plus stenting. However, patients treated by cutting balloon plus stenting were excluded, and thus 65 patients were enrolled in this study. Two groups of patients with LAD ostial disease were compared. The study group was divided into 2 groups according to the following criteria: group I was comprised of patients who had been treated with DCA, with or without adjunctive balloon or stenting; and group II was comprised of patients who had been treated with stenting alone.

Notably, all stenting of lesions was guided by intravascular ultrasound (IVUS). Comparative quantitative angiographic analysis of groups I and II was conducted, and comparative intravascular ultrasound measurements were made.

This protocol was approved by the hospital ethics committee and is in accordance with the Declaration of Helsinki. Written informed consent was obtained from every patient.

Definitions

Procedural success was defined as a residual stenosis of $< 50\%$ without cardiac complications. Optimal debulking following the atherectomy was considered when residual plaque + media CSA (atherosclerotic plaque) was $< 60\%$.

Angiographic restenosis was defined as $\geq 50\%$ diameter stenosis of the treated site at the follow-up examination.

Target lesion revascularization was defined as the need for repeat balloon angioplasty in angiographic restenosis cases.

Loss index was defined as late loss / acute gain.

Procedural details

Directional atherectomy

First, under a 10- or 8-Fr guiding catheter, a 6- or 7-Fr atherectomy device was directed over a 0.014-in guidewire and positioned across the lesion. Multiple cuts were then made, guided by IVUS, to debulk the lesion. The aim was to achieve an angiographic residual diameter stenosis of $< 20\%$ by visually estimating optimal lesion debulking.

Intraobserver variability

To overcome intraobserver variability, quantitative coronary angiography analysis (QCA) and IVUS were measured twice. The data used were the mean value of 2 measurements.

IVUS procedures and measurements

IVUS imaging was conducted using a 30-MHz transducer-tipped catheter (Ultracross 3.2, Boston Scientific, USA). After the machine settings had been optimized, images were recorded on an S-VHS videotape recorder, following an intracoronary bolus injection of nitroglycerine. The IVUS system was automatically withdrawn at a rate of 1 mm/s during the imaging sequence. Ultrasound images were

recorded on high-resolution s-VHS tape for off-line analysis. A single observer made the off-line ultrasound measurements. To reduce data variability, all IVUS measurements were repeated, and the average of the 2 values was used in the analysis. The external elastic membrane cross-sectional area (EEM CSA), representing the total arterial CSA, was measured by tracing the leading edge of the adventitia. The following parameters were measured at the site of the lesion:

- (1) minimal lumen area (MLA) (mm²)
- (2) plaque + media CSA (EEM CSA minus lumen CSA); and
- (3) Percentage area stenosis (100 x / lesion EEM CSA).

Quantitative coronary angiographic analysis

Coronary angiography was conducted following the intracoronary administration of nitroglycerin. Off-line computerized QCA measurements were made using the CMS system (version 4.0, MEDIS). The percentage diameter stenosis, minimal luminal diameter (MLD), and reference vessel diameter were measured before and after the intervention, and at both follow-up visits utilizing diastolic frames in a single, matched view of the smallest luminal diameter. The reference vessel diameter was the mean diameter of the proximal and distal sites of the LAD ostial lesion.

Post-procedure management and follow-up

Aspirin (80 mg/day) was administered before all procedures; ticlopidine (300 mg/day) was administered to stented patients both before and after the procedure. Follow-up data for angina recurrence, target lesion revascularization, myocardial infarction, coronary artery bypass surgery, and death were obtained during outpatient clinic visits. Patients were asked to return for angiographic follow-up after 3 and 6 months.

Statistical analysis and data management

Statistical analyses were conducted by applying the SPSS Windows (SPSS, Chicago, IL, USA) statistical package. Categorical variables, given as percentages were evaluated by utilizing Chi-square or Fisher’s tests (when the expected cell frequency was < 5). Continuous variables are presented as the mean ± SD and compared using unpaired Student’s *t*-test.

Repeated-measures ANOVA was used to analyze serial changes in diameter of the 2 groups. A *p* value of < 0.05 was considered significant.

RESULTS

Demographics and clinical characteristics (Table 1)

Clinical parameters at the baseline did not significantly differ between groups I and II. Treatments of the members of the DCA group were finished using a 7-Frcutter for 24 lesions (70%) and a 6-Frcutter for 10 lesions (30%), and involved 11 ± 7 cuts per lesion. Adjunctive balloon angioplasty was performed on 22 lesions to obtain optimal results, while adjunctive stenting was used on 35% (12/34) of the lesions due to a suboptimal result after adjunctive balloon angioplasty, in order to obtain optimal results.

Quantitative angiography

DCA vs. stenting alone: results at 3 months (Table 2)

The diameter of the reference vessel, the minimal diameter of the lumen, the diameter of the stenosis, and the length of the lesion prior to intervention were similar across both groups (*p* > 0.05). Following the intervention, group I had a larger minimal lumen diameter than group II (3.37 ± 0.45 vs. 3.14 ± 0.49 mm, *p* = 0.03). The reference vessel diameter, diameter of the stenosis, stent length, and acute gain were similar for both groups (*p* > 0.05).

Table 1. Demographic and Clinical Characteristics

	DCA (n = 34)	Stent alone (n = 31)	<i>p</i> Value
Age (years) (mean ± SD)	69 ± 11	66 ± 10	0.38
Males, n (%)	27 (79%)	20 (65%)	0.10
Diabetes mellitus, n (%)	13 (38%)	13 (40%)	0.60
Systemic hypertension, n (%)	19 (56%)	19 (61%)	0.55
Hyperlipidemia, n (%)	14 (41%)	15 (48%)	0.45
Cigarette smoking, n (%)	15 (44%)	14 (45%)	0.56
Family history, n (%)	2 (6%)	3 (10%)	0.22
Prior myocardial infarction, n (%)	11 (32%)	10 (32%)	0.48
Previous coronary bypass, n (%)	2 (6%)	2 (6%)	0.42
Multivessel coronary disease, n (%)	26 (76%)	23 (74%)	0.56
Chronic total occlusions, n (%)	3 (7%)	4 (10%)	0.32
Left ventricle ejection fraction (%) (mean ± SD)	59 ± 14	55 ± 16	0.36

Data are presented as mean ± SD.

Table 2. Quantitative Angiographic Measurements of Left Anterior Descending Artery Ostium Stenosis

	DCA (n = 34)	Stent (n = 31)	p value
Pre-intervention			
Reference diameter (mm)	3.27 ± 0.35	3.26 ± 0.26	0.95
Min. luminal diameter (mm)	0.92 ± 0.27	0.88 ± 0.19	0.82
Diameter stenosis (%)	71.8 ± 7.8	73.3 ± 5.1	0.85
Lesion length (mm)	8.62 ± 5.80	9.28 ± 7.36	0.70
Post-intervention			
Reference diameter (mm)	3.32 ± 0.24	3.24 ± 0.31	0.42
Min. luminal diameter (mm)	3.37 ± 0.45	3.14 ± 0.49	0.03
Diameter stenosis (%)	-1.5 ± 12.8	3.1 ± 13.3	0.34
Stent length (mm)	12.3 ± 6.8	13.2 ± 7.0	0.75
Acute gain (mm)	2.45 ± 0.54	2.26 ± 0.49	0.64
Follow-up			
Reference diameter (mm)	3.24 ± 0.28	3.16 ± 0.23	0.56
Min. luminal diameter (mm)	2.51 ± 0.81	2.08 ± 0.76	0.03
Diameter stenosis (%)	22.5 ± 23.5	33.7 ± 25.3	0.07
Late loss (mm)	0.86 ± 0.86	1.06 ± 0.71	0.10
Loss index	0.33 ± 0.30	0.48 ± 0.33	0.04

Data are presented as the mean ± SD.

At the time of the 3-month follow-up, group I had a larger minimal lumen diameter (2.51 ± 0.81 vs. 2.08 ± 0.76 mm, $p = 0.03$) and a smaller-diameter stenosis ($22.5\% \pm 23.5\%$ versus $33.7\% \pm 25.3\%$, $p = 0.07$) than group II. Moreover, group I also had achieved a lower loss index than group II (0.33 ± 0.30 vs. 0.48 ± 0.33 , $p = 0.04$).

Effect of the procedure on the LCX ostium (Table 3)

Fifteen cases in group I and 11 in group II already had an ostial stenosis in the LCX before the intervention and were excluded. The effect of the treatment of the LAD on the LCX ostium was studied after excluding those cases. The immediate plaque shift (meaning $\geq 50\%$ diameter stenosis in the LCX ostium) occurred in 40% (8/20) of lesions in the stenting group. The kissing balloon technique was used for these lesions. No further stents were delivered to the LCX ostium. Of the lesions treated with the kissing balloon technique, 25% (5/20) had developed new lesions in the LCX ostium or the left main artery at the 6-month follow-up. No plaque shift occurred in the DCA group ($p < 0.05$).

Results are presented in Table 3 and Figure 1. In the DCA group, the minimal lumen diameter of the LCX ostium did not change during DCA and had not

Table 3. Quantitative Angiographic Measurements of Left Circumflex Artery Ostium Stenosis

	Directional coronary atherectomy (n = 19)	Stenting alone (n = 20)	p value
Pre-intervention			
Reference diameter (mm)	3.16 ± 0.49	3.19 ± 0.33	0.85
Min. luminal diameter (mm)	2.73 ± 0.49	2.76 ± 0.45	0.95
Diameter stenosis (%)	13.6 ± 10.4	13.5 ± 9.4	
Post-intervention			
Reference diameter (mm)	3.12 ± 0.44	3.15 ± 0.29	0.95
Min. luminal diameter (mm)	2.70 ± 0.58	2.59 ± 0.56	0.02
Diameter stenosis (%)	13.5 ± 10.6	17.8 ± 14.1	0.60
Follow-up			
Reference diameter (mm)	3.08 ± 0.46	3.10 ± 0.34	0.87
Min. luminal diameter (mm)	2.69 ± 0.50	2.43 ± 0.73	0.03
Diameter stenosis (%)	12.7 ± 10.8	21.6 ± 21.0	0.02

Data are presented as the mean ± SD.

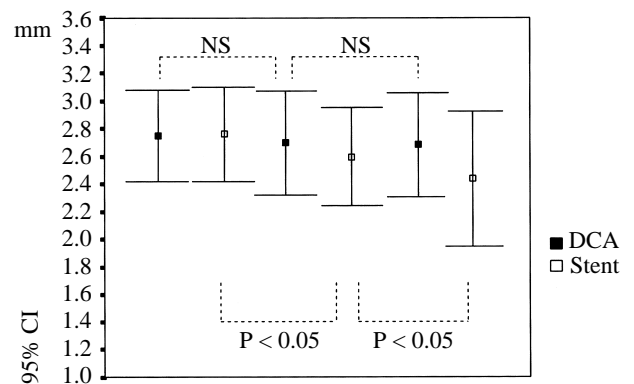


Fig. 1 Changes in minimal lumen diameter of the left circumflex artery (LCX) ostium before the intervention, after the intervention, and at the 3-month follow-up. The diameter was unchanged with DCA, yet it had narrowed with stenting alone. Before, before angioplasty; After, after angioplasty; Follow-up, at repeated angiography.

changed at the 3-month follow-up. In contrast, the minimal lumen diameter of the LCX ostium in group II was significantly reduced. At the 3-month follow-up, the diameter had also decreased.

IVUS analysis (Table 4)

In the DCA group, IVUS was performed both before and after the intervention on 34 lesions. Group II included a total of 31 lesions. The vessel's cross-sectional area (CSA), minimal lumen area

Table 4. IVUS Measurements of Left Anterior Descending Artery Ostial Stenosis

	Descending coronary atherectomy (n = 34)	Stent alone (n = 31)	p value
Pre-intervention			
Vessel CSA (mm ²)	13.30 ± 1.80	13.25 ± 2.56	0.94
MLA (mm ²)	2.41 ± 1.05	2.35 ± 0.82	0.85
Area stenosis (%)	81.9 ± 8.9	82.3 ± 6.7	0.70
Plaque-media CSA	10.89 ± 2.22	10.90 ± 2.54	0.35
Post-debulking			
Vessel CSA (mm ²)	13.41 ± 2.04	-	
MLA (mm ²)	7.33 ± 1.90	-	
Area stenosis (%)	45.3 ± 11.1	-	
Plaque-media CSA (mm ²)	6.08 ± 1.72	-	
Post-intervention			
Vessel CSA (mm ²)	13.87 ± 2.22	13.70 ± 2.57	0.65
MLA (mm ²)	8.42 ± 1.55	7.24 ± 1.59	0.24
Area stenosis (%)	39.3 ± 9.6	47.2 ± 7.2	0.05
Plaque-media CSA (mm ²)	5.45 ± 1.87	6.46 ± 1.79	0.01

Abbreviations: CSA: cross-sectional area; MLA: minimal luminal area.

Data are presented as the mean ± SD.

(MLA), area of stenosis, and plaque-media CSA were similar across both groups. After the intervention, group I exhibited a smaller area of stenosis (39.3% ± 9.6% vs. 47.2% ± 7.2%, $p = 0.05$) and a lower plaque-media CSA (5.45 ± 1.87 vs. 6.46 ± 1.79 mm², $p = 0.01$) than group II. Notably, in group II, the IVUS interrogation resulted in balloon upsizing and/or higher inflation pressure in 12 lesions (39%). In those lesions, the mean change in balloon upsizing was 0.25 ± 0.25 mm, and the mean change in inflation pressure was 4.3 ± 3.5 atm.

Clinical outcomes and event-free survival (Table 5)

No ST-elevated myocardial infarction, coronary artery bypass surgery, or mortality were recorded in the 2 groups. The rates of event-free survival significantly differed among the 2 groups ($p = 0.04$). Patients who underwent stenting alone experienced more events than did patients treated with DCA therapies (Fig. 2). The degree and frequency of angina pectoris were not studied in the 2 groups.

At the 3-month follow-up, group I exhibited a restenosis rate of 27% (9/34), whereas group II exhibited a rate of 36% (11/31) ($p = 0.30$); the TLRs of the 2 groups were 23% (8/34) and 32% (10/31),

Table 5. Three- and 6-Month Follow-up of Left Anterior Descending Artery Ostial Lesions

	DCA	Stenting alone	p value
3-month follow-up			
n	34	31	
Restenosis	9 (26.5%)	11 (35.5%)	0.30
Target lesion revascularization	8 (23.5%)	10 (32.2%)	0.30
6-month follow-up			
Cumulative n	34	31	
Cumulative restenosis	11 (32.4%)	15 (48.4%)	0.04
Cumulative target lesion revascularization	11 (32.4%)	15 (48.4%)	0.04

Abbreviation: DCA: directional coronary atherectomy.

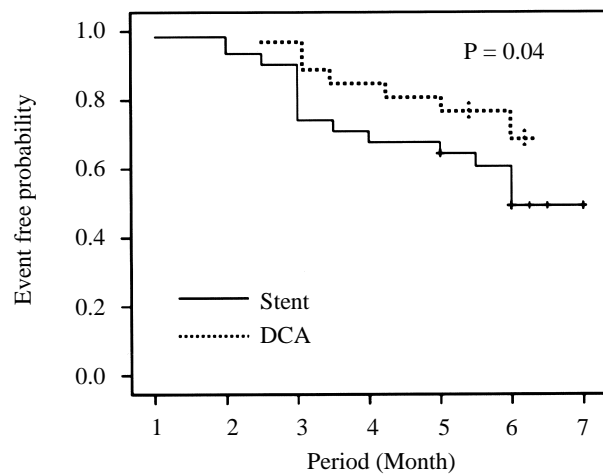


Fig. 2 Event-free probability from revascularization, myocardial infarction, or death. Patients assigned to the stenting-alone group are indicated by the solid line; patients assigned to the DCA group are indicated by the dashed line.

respectively ($p = 0.30$). At the 6-month follow-up, group I exhibited a cumulative restenosis rate of 32% (11/34) in contrast to 48% (15/31) in group II ($p = 0.04$), while the cumulative TLRs of the 2 groups were 32% (11/34) and 48% (15/31), respectively ($p = 0.04$).

Results of stenting after optimal debulking and optimal debulking alone (Table 6)

Optimal debulking followed by stenting was employed to treat 11 lesions. Optimal debulking alone was utilized to treat 18 lesions. Both groups exhibited similar reference vessel diameters and

lesion lengths prior to the intervention ($p > 0.05$). Notably, the post-intervention MLD was larger in the group that underwent optimal debulking plus stenting than in the group in which optimal debulking alone was performed ($p = 0.04$). Moreover, the acute gain was also larger in the optimal debulking plus stenting group than in the group that underwent only optimal debulking ($p = 0.05$).

With reference to the angiographic and clinical outcomes, the optimal debulking plus stenting group exhibited a restenosis rate of 9% (1/11), in contrast to 33% (6/18) in the optimal debulking alone group ($p = 0.05$). Furthermore, the optimal debulking plus stenting group also exhibited a lower cumulative restenosis rate after 6 months than the group that underwent optimal debulking alone (9% vs. 36%, $p = 0.05$). Optimal debulking followed by stenting minimized the restenosis and target lesion revascularization rates.

Figure 3 shows a case example of optimal debulking followed by stenting used to treat an LAD ostial lesion.

DISCUSSION

Conventional balloon angioplasty is ineffective in treating ostial lesions, causing high immediate recoil and high long-term restenosis. Recent studies

Table 6. Quantitative Angiographic Measurements and Clinical Results of the Directional Coronary Atherectomy (DCA) Groups

	Optimal DCA (n = 18)	Optimal DCA plus stenting (n = 11)	p value
Pre-intervention			
Reference diameter (mm)	3.26 ± 0.45	3.27 ± 0.41	0.85
Min. luminal diameter (mm)	0.92 ± 0.27	0.88 ± 0.19	0.40
Diameter stenosis (%)	71.8 ± 7.4	73.1 ± 6.1	0.56
Lesion length (mm)	8.58 ± 5.80	8.60 ± 6.36	0.95
Post-intervention			
Reference diameter (mm)	3.28 ± 0.24	3.30 ± 0.31	0.84
Min. luminal diameter (mm)	3.24 ± 0.56	3.62 ± 0.40	0.04
Diameter stenosis (%)	1.2 ± 10.8	-9.7 ± 4.3	0.07
Stent length (mm)		13.0 ± 6.0	
Acute gain (mm)	2.33 ± 0.59	2.77 ± 0.56	0.05
Follow-up (at 3 months)			
Reference diameter (mm)	3.24 ± 0.28	3.28 ± 0.23	0.64
Min. luminal diameter (mm)	2.17 ± 0.71	2.82 ± 0.66	0.01
Diameter stenosis (%)	33.0 ± 23.5	14.0 ± 26.3	0.02
Late loss (mm)	1.07 ± 0.76	0.80 ± 0.71	0.15
Loss index	0.46 ± 0.32	0.29 ± 0.29	0.12
3-month follow-up			
Restenosis	33% (6/18)	9% (1/11)	0.05
6-month follow-up			
Cumulative restenosis	36% (7/18)	9% (1/11)	0.05

Abbreviations: DCA: directional coronary atherectomy.

Data are presented as the mean ± SD.

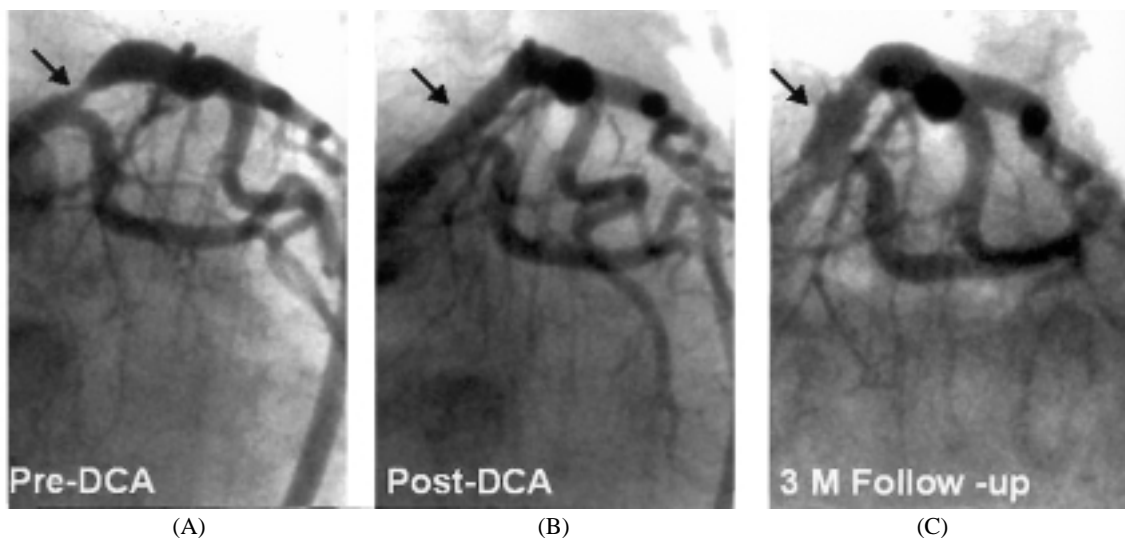


Fig. 3 (A) Baseline angiogram of the left coronary artery, showing a left anterior descending artery (LAD) ostial lesion. (B) Post-procedure angiogram of optimal debulking. (C) Coronary angiogram at the 3-month follow-up.

have confirmed that both bare metal stenting alone and DCA yield better angiographic results and a higher success rate than PTCA.^(7,17-21) Importantly, this work verifies that both stenting alone and debulking devices provide safe and effective treatment for LAD ostial lesions and yield satisfactory angiographic results. Achieving optimal positioning is difficult because of poor radiopacity and residual narrowing during stent expansion. This can be verified if intracoronary ultrasound is performed following stent deployment. Under the guidance of IVUS, the stents can be dilated using larger balloons or greater pressure. Accordingly, the same acute gain in lumen diameter as that obtained using DCA was achieved in this study. The linear regression analysis showed a positive association between acute gain and late loss in both treatment groups.

The mechanical scaffold of the stent freezes the lumen gain obtained after balloon dilatation, while almost completely eliminates the mural recoil. Notably, the outward extrusion of the plaque during balloon dilatation was limited by the mechanical resistance of the fibrous adventitial layers and resulted in axial redistribution of the plaque. The shifting of the plaque and tears in the edge are likely to be the main causes of focal restenosis at the edges of the stent. Plaque shift following stenting also compromises the ostium of the side branches which originate in stented segments. This compromise induces severe narrowing or occlusion of the side branches, especially in the presence of preexisting ostial narrowing. Although dilatation through the stent struts may restore side-branch patency, the residual narrowing often remains. DES implantation was performed according to the practice of fully covering the diseased segment (from the left main to the LAD). This technique is not suitable when the diameter of the left main is larger than that of the LAD. The plaque shifting to the LCX ostium following stenting is still a problem.

This study established that the debulking of LAD ostial lesions by DCA did not cause any significant narrowing of the ostium of the LCX. In contrast, stenting of the LAD ostial segment resulted in a significantly narrower ostium of the LCX than that obtained with DCA. The narrowed ostium of the LCX was treated with the kissing balloon technique. Unfortunately these lesions also developed new stenosis in the LCX ostium or the left main artery.

However, the DCA group did not exhibit plaque shifting ($p = 0.02$).

The extent of neointimal hyperplasia after stenting is proportional to the extent of the initial stretching of the vessel walls.⁽²²⁾ Notably, the absolute quantity and consistency of the plaque were the primary factors examined when determining the force required to expand the stent. Increasing the plaque burden may have caused the increased rate of late lumen loss following stenting.⁽²³⁾ The removal of the atherosclerotic plaque with DCA before stenting may attenuate the late lumen loss and reduce the incidence of stent restenosis.

DCA is most effective for treating easily accessible eccentric lesions with very large plaque burdens. Although the acute gain in lumen diameter was the same for both groups, the post-intervention MLA was larger in the group treated using debulking devices. That group also displayed larger follow-up MLDs and smaller-diameter stenoses than the group with stenting alone, as well as late lumen loss which led to lower restenosis and target lesion revascularization rates. Although the DCA strategy was more effective than stenting alone in treating LAD ostial lesions, the restenosis rate (27%) at the 3-month follow-up was still high.

After the atherectomy, the vessel wall undergoes a process of chronic recoil that is partially responsible for the late restenosis.^(24,25) The method of DCA plus stenting yielded a higher acute lumen gain and late lumen loss similar to those obtained using DCA alone. This phenomenon caused the loss index to be lower in the DCA-plus-stenting group than in the group that underwent DCA alone.

Should stenting occur after optimal debulking?

From the results given in Table 6, optimal debulking combined with stenting achieved larger post-intervention MLD and acute gain. Optimal debulking followed by stenting minimized the restenosis and target lesion revascularization rates (9% vs. 36%, $p = 0.05$). These results suggest that the stent should be employed even if optimal debulking has been applied.

The use of mammary artery bypass surgery for the treatment of patients with stable angina and isolated severe proximal stenosis of the LAD with normal ventricular function was associated with a higher event-free survival rate than coronary angioplasty or

medical strategies alone during a 5-year follow-up period.^(26,27) Ostial LAD stenosis tends to recur more often and requires more re-interventions after initial successful PCI than non-ostial and proximal LAD stenoses, especially within the first year. Therefore, published data about revascularization for proximal LAD stenosis suggest that ostial LAD stenosis will benefit more from bypass surgery compared to PCI than non-ostial but proximal LAD stenosis.⁽²⁸⁾ If a risk of restenosis and an increased need for subsequent interventions are acceptable, optimal debulking followed by stenting remains a suitable therapeutic option and simpler alternative to bypass surgery in treating ostial LAD stenosis. However, systemic follow-up angiographic studies are warranted.

Study limitations

This investigation was a nonrandomized, retrospective study of a single center, and thus has several limitations. The number of patients was relatively small. Optimal DCA was not achieved in every DCA case. This produced different results for DCA, optimal DCA, DCA plus stenting, and optimal DCA plus stenting. Results were not compared among these subgroups. Since IVUS-guided stenting was used in most cases, it is unclear whether angiographic guidance alone could have achieved similar outcomes.

REFERENCES

1. Ellis SG, Roubin GS, King SB, Douglas JS, Weintraub WS, Thomas RG. Angiographic and clinical predictors of acute closure after native vessel coronary angioplasty. *Circulation* 1988;77:373-9.
2. Stewart JT, Ward DE, Davies MJ, Pepper JR. Isolated coronary ostial stenosis. *Eur Heart J* 1987;8:917-20.
3. Rensing BJ, Hermann WR, Strauss BH, Serruys PW. Regional differences in elastic recoil after percutaneous transluminal coronary angioplasty: a quantitative angiographic study. *J Am Coll Cardiol* 1991;17:34-8B.
4. Mathias DW, Mooney JF, Lange HW, Goldenberg IF, Gobel FL, Mooney MR. Frequency of success and complications of coronary angioplasty of a stenosis at the ostium of a branch vessel. *Am J Cardiol* 1991;67:491-5.
5. Brown R, Kochar G, Mariet AR, Banka VS. Effects of coronary angioplasty using progressive dilation on ostial stenosis of the left anterior descending artery. *Am J Cardiol* 1993;71:245-7.
6. Garcia E, Serruys PW, Dawkins K, Hanet C, Rutsch W, Riele H, Crean P, Hopp H, Materne P, Binzaghi G. BEN-ESTENT-II trial: final results of visit II & III: a 7-month follow-up. *Eur Heart J* 1997;18:1960.
7. Zampieri P, Colombo A, Almagor Y, Maiello L, Finci L. Results of coronary stenting of ostial lesions. *Am J Cardiol* 1994;73:901-3.
8. Morice MC, Serruys PW, Sousa JE, Fajadet J, Ban Hayashi E, Perin M, Colombo A, Schuler G, Barragan P, Guagliumi G, Molnar F, Falotico R. A randomized comparison of a sirolimus-eluting stent with a standard stent for coronary revascularization. *N Engl J Med* 2002;346:1773-80.
9. Colombo A, Drzewiecki J, Banning A, Grube E, Hauptmann KE, Silber S, Dudek D, Fort S, Schiele F, Zmudka K, Guagliumi G, Russell ME, for the group ftTIs. Randomized study to assess the effectiveness of slow- and moderate-release polymer-based paclitaxel-eluting stents for coronary artery lesion. *Circulation* 2003;108:788-94.
10. Moses JW, Leon MB, Popma JJ, Fitzgerald PJ, Holmes DR, O'Shaughnessy C, Caputo RP, Kereiakes DJ, Williams DO, Teirstein PS, Jaeger JL, Kuntz RE. Sirolimus-eluting stents versus standard stents in patients with stenosis in a native coronary artery. *N Engl J Med* 2003;349:1315-23.
11. Schofer J, Schluter M, Gershlick AH, Wijns W, Garcia E, Schampaert E, Breithardt G. Sirolimus-eluting stents for treatment of patients with long atherosclerotic lesions in small coronary arteries: double-blind, randomised controlled trial (E-SIRIUS). *Lancet* 2003;362:1093-9.
12. Stone GW, Ellis SG, Cox DA, Hermiller J, O'Shaughnessy C, Mann JT, Turco M, Caputo R, Bergin P, Greenberg J, Popma JJ, Russell ME. A polymer-based, paclitaxel-eluting stent in patients with coronary artery disease. *N Engl J Med* 2004;350:221-31.
13. Baim DS, Cutlip D, Sharmin SK, Ho KKL, Fortuna R, Schreiber TL, Feldman R, Shani J, Senerchia C, Zhang Y, Lansky A, Popma J, Kuntz R, for the BOAT Investigators. Final results of the balloon versus optimal atherectomy trial (BOAT). *Circulation* 1998;97:322-31.
14. Nakhjavan FK, Goldman AP, Hutt GH, Wertheimer JH, Yazdanfar S, Maranhao V, Weiner R. Percutaneous transluminal coronary angioplasty of the "very proximal" coronary artery stenosis. *Cathet Cardiovasc Diagn* 1987;13:87-92.
15. Boxt LM, Meyerovitz MF, Taus RH, Gantz P, Friedman PL, Levine DC. Side branch occlusion complicating percutaneous transluminal coronary angioplasty. *Radiology* 1986;161:681-3.
16. Meier B, Gruentzig AR, King SB, Douglas JS, Hollman J, Ischinger T, Aueron F, Galan K. Risk of side branch occlusion during coronary angioplasty. *Am J Cardiol* 1984;53:10-4.
17. Rocha-Singh K, Morris N, Wong C, Schatz RA, Teirstein PS. Coronary stenting for the treatment of ostial stenosis of native coronary arteries or aortocoronary saphenous venous grafts. *Am J Cardiol* 1995;75:26-9.
18. Hinohara T, Rowe MH, Robertson GC, Selmon MR, Braden L, Leggett JH, Vetter JW, Simpson JB. Effect of

- lesion characteristics on outcome of directional coronary atherectomy. *J Am Coll Cardiol* 1991;17:1112.
19. Popma JJ, Dick RL, Haudenschild CC, Topol EJ, Ellis SG. Atherectomy of right coronary ostial stenosis: Initial and long-term results, technical features and histologic findings. *Am J Cardiol* 1991;67:431-3.
 20. Sabri MN, Cowley MJ, DiSciascio G, DeBottis D, Kelly K, Goudreau E, Vetrovec GW. Immediate results of interventional devices for coronary ostial narrowing with angina pectoris. *Am J Cardiol* 1994;73:122-5.
 21. Asakura Y, Takagi S, Ishikawa S, Asakura K, Sueyoshi K, Sakamoto M, Takatsuki S, Oda T, Nakagawa M, Furukawa Y, Oyamada K, Iwanaga S, Ogawa S, Hinohara T. Favorable strategy for the ostial lesion of the left anterior descending coronary artery: Influence on narrowing of circumflex coronary artery. *Cathet Cardiovasc Diagn* 1998;43:95-100.
 22. Rogers C, Edelman E. Endovascular stent design dictates experimental restenosis and thrombosis. *Circulation* 1995;91:2195-3001.
 23. Moussa I, Di Mario C, Moses J, Di Francesco L, Reimers B, Tobis J, Colombo A. The impact of preintervention plaque area as determined by intravascular ultrasound on luminal renarrowing following coronary stenting [Abstract]. *Circulation* 1996;94:1528.
 24. Moussa I, Moses J, Di Mario C, Busi G, Reimers B, Kobayashi Y, Albiero R, Ferraro M, Colombo A. Stenting after optimal lesion debulking (SOLD) registry: angiographic and clinical outcome. *Circulation* 1998;98:1604-9.
 25. Mintz GS, Popma JJ, Hong MK, Pichard AD, Kent KM, Satler LF, Leon MB. Intravascular ultrasound to discern device-specific effects and mechanisms of restenosis. *Am J Cardiol* 1996;78 (Suppl 3A):18-22.
 26. Devrey EA, Mintz GS, Birgelen C, Kimura T, Noboyoshi M, Popma JJ, Serruys PW, Leon MB. Serial volumetric (three-dimensional) intravascular ultrasound analysis of restenosis after directional coronary atherectomy. *J Am Coll Cardiol* 1998;32:1874-80.
 27. Hueb WA, Soares PR, Almeida De Oliveira S, Arie S, Cardoso RH, Wajsbrot DB, Cesar LA, Jatene AD, Ramires JA. Five-year follow-up of the medicine, angioplasty, or surgery study (MASS): a prospective, randomized trial of medical therapy, balloon angioplasty, or bypass surgery for single proximal left anterior descending coronary artery stenosis. *Circulation* 1999;100(19 Suppl II):107-13.
 28. Killen DA, Wathanacharoen S, Reed WA, Piehler JM, Borkon AM, Gorton ME, Meuhlebach GF. Coronary artery bypass for isolated disease of the left anterior descending artery. Late survival of 648 patients. *Texas Heart Inst J* 1998;25(3):181-4.

比較冠狀動脈粥狀切除術及直接的支架植入用於冠狀動脈左前降枝開口端的病變的結果

鍾昌珉 中村茂¹ 加藤修¹

背景：冠狀動脈左前降枝 (LAD) 的開口端 (ostium) 病變在冠狀動脈疾病中是一個特別的族群，因為純使用氣球血管成形術的結果不理想並且增加再狹窄 (restenosis) 的比率。目前有幾個非氣球血管成形術的方法已經用來改進這樣的病變的處理結果。

方法：這是回溯性的研究。比較冠狀動脈粥狀切除術 (DCA) 及直接的支架植入 (stenting) 用於冠狀動脈左前降枝的開口端 (ostium) 的病變的結果，以及這些治療對左迴旋枝 (LCX) 開口端的影響。上述治療方法用於冠狀動脈左前降枝 (LAD) 的開口端 (ostium) 的病變共有 65 位病患被研究。病患被分成兩組：第一組使用冠狀動脈粥狀切除術 (DCA, n = 34) 和第二組使用直接的支架植入 (stenting, n = 31)。

結果：上述的治療後，最小管腔的直徑於第一組比第二組大 (3.37 + 0.45 對 3.14 + 0.49 毫米, $p < 0.05$)。在 3 個月後追蹤，最小管腔的直徑於第一組仍比第二組大 (2.51 + 0.81 與 2.08 + 0.76 毫米, $p = 0.03$) 和於直徑狹窄度 (diameter stenosis) 第一組仍比第二組小 (22.5 + 23.5 對 33.7 + 25.3 %)。而且，第一組的損失索引 (loss index) 比第二組小 (0.33 + 0.30 對 0.48 + 0.33, $p < 0.05$)。第一組再狹窄率 (restenosis) 為 27% (9/34)，第二組為 36% (11/31)。在 6 個月追蹤，第一組的累積再狹窄率 (cumulative restenosis) 為 32% (11/34)，比第二組的 48% (15/31) 還低 ($p = 0.04$)。

在第一組冠狀動脈粥狀切除術後及追蹤中未發現癥塊的移動及造成左迴旋枝 (LCX) 開口端內徑的改變。若僅有支架植入 (第二組)，於初期及追蹤中將發現左迴旋枝開口端內徑的狹窄。理想的冠狀動脈粥狀切除術 (optimal DCA) 後再植入支架的 3 個月再狹窄率為 9% (1/11)，6 個月累積的再狹窄率仍為 9%；而僅做理想的冠狀動脈粥狀切除術後未植入支架再狹窄率為 33% (6/18)，6 個月累積的再狹窄率為 36% (p 值皆為 0.05)。

結論：對於冠狀動脈左前降枝 (LAD) 開口端的治療，冠狀動脈粥狀切除術比僅有 IVUS 指引下的支架植入效果要好，並且無癥塊移動的危險。理想的冠狀動脈粥狀切除術 (Optimal DCA) 後再支架植入，將可能獲得較佳的結果。

(長庚醫誌 2005;28:689-98)

關鍵字：冠狀動脈粥狀切除術，支架，開口端。

長庚紀念醫院 嘉義院區 心臟內科；¹京都桂病院 心臟血管中心

受文日期：民國94年5月18日；接受刊載：民國94年8月16日

通訊作者：鍾昌珉醫師，長庚紀念醫院 心臟內科。嘉義縣613朴子市嘉朴路西段6號。Tel.: (05)3621000轉2854; Fax: (05)3622005; E-mail: cmchung02@hotmail.com