

PET/CT in Oncology: a Major Technology for Cancer Care

Peter J. Ell, MD

PET-CT can image tumor metabolism, proliferation, hypoxia, and apoptosis with precise anatomic image fusion and will become an essential tool in the management of patients with cancer by its ability to assess the extent and severity of disease and treatment response. F-18 fluoro-2-deoxy-D-glucose (FDG) is the most frequently used radiopharmaceutical today and new F-18 labeled ligands are under development. It has changed dramatically the management of numerous cancers such as brain tumors, head and neck cancers, thyroid cancer, parathyroid cancer, lung cancer, esophageal cancer, lymphoma, pancreatic cancer, colorectal cancer, and many others. Its utility for non-cancerous conditions is also gradually established. In this article the basic technology, the ligands available for routine clinical applications, and expected developments in the near future will be addressed. PET-CT will be used with increasing frequency and will become progressively used as a surrogate marker for disease response. Novel ligands, labeled with F-18, will further increase the clinical utility of this technology. (*Chang Gung Med J* 2005;28:274-83)

Key words: PET-CT, oncology, fluoro-2-deoxy-D-glucose (FDG).

Positron emission tomography (PET) is a minimally invasive imaging modality that offers high-resolution data and makes use of biologically active radiopharmaceuticals. From the best practice today the following statements can be made: the metabolic response precedes the anatomic change; the response in lymphoma and germ cell tumor is seen in hours; and PET/computed tomography (PET/CT) or PET only can assess new biological markers for proliferation, hypoxia, apoptosis and a number of other processes.

In the rapidly changing world of health technology, PET/CT has now gained a place of prominence. The clarity of the data achieved, the routine implementation of image fusion in a multimodality setting, and the apparent ease with which labeled fluoro-2-deoxy-D-glucose (FDG) can be used to depict and follow up cancer are clearly the causes of the rapid acceptance of this technological development within the community of cancer caregivers. Patients and

caregivers now speak with one voice when describing the momentous advantages which have been gained with the introduction of this approach.

In this brief summary, the basic technology, the ligands available for routine clinical applications, and expected developments in the near term will be addressed.

Technology

PET and CT have been with us for some 50 and 30 years, respectively. But it was only in mid-2001 when the first commercially available PET/CT scanner was installed in a hospital environment (Zurich, Switzerland).

The first PET/CT scanner in UK was installed in January, 2002. Amazingly in a very short period of time, some 200 PET/CT scanners have been sold worldwide and PET-only devices are rapidly being seen as a technology of the past. Even diehard PET experts have not predicted such a rapid development

From the Department Nuclear Medicine - UCL, London, UK.

Received: Feb. 22, 2005; Accepted: Feb. 22, 2005

Address for reprints: Dr. Peter J Ell, University of London, Institute of Nuclear Medicine, The Middlesex Hospital, Mortimer Street, London W1T3AA, UK. Tel: (020) 7631-1066; Fax: (020)7436-0603

(Table 1).

The rapid introduction of PET/CT has evolved in an astonishing fashion. Benefiting from a resurgence of spiral CT in respect to magnetic resonance (MR) imaging, spiral CT scanners have evolved from the initial 2-slice devices to 4- and 8-slice scanners. In the last 24 months these developments have not stopped. Sixteen-slice scanners are now seen as a routine requirement, and 32-, 40- and even 64-slice spiral CT scanners are now available or leaving the drawing board. It seems certain that future PET/CT scanners will incorporate 16-slice scanners, but it appears much less certain what the role of 32- and 64-slice devices will be and what, if anything, these devices will offer in terms of a multimodality imaging device such as a PET/CT instrument. There is the seduction of one complete imaging study for all - answering all the questions in one setting - but the downside will be that many patients would be over-investigated. Some of these concerns have recently emerged from the over-utilization of whole-body spiral CT screening. Nevertheless, technological progress on the PET component of a PET/CT scanner is also evolving. New crystals have matured since the huge success of BGO (bismuth germanate), and most manufacturers are evolving new strategies for PET detector assemblies. This is a rapidly evolving scenario, with hard-to-predict outcomes. That PET/CT scanners will become faster is nevertheless

beyond doubt. Scanning times from mid-brain to mid-thigh have been halved in the last 3-5 years. The expected impact of 2D versus 3D whole-body imaging is making its own mark, and scanning times for the same amount of tracer given (in MBq) are also likely to improve further. It will be interesting to see how time-of-flight and avalanche photodiode detectors will impact the design of a new generation of scanners and to see the impact of these designs on new detector technologies.

These rapid developments have also had significant impact on the design of fast throughput PET/CT scanning. The 60-minute minimal wait between the tracer administration to the patient and the actual scanning is now requiring new designs in the patient-waiting areas; considerations of radiation protection to staff will become more relevant. If only we could have a tracer as effective as FDG without the requirement of a 1-hour wait!

In summary, the main merits of PET/CT imaging technology include faster patient throughput (30% faster), higher patient acceptance (shorter time for lying on the scanner), routine and instantaneous image fusion, single study from the same scanning bed, much improved precision in the localization of the lesion, increased lesion detection, much faster learning curve, greater clinical acceptance at case conference and multidisciplinary meetings.

Table 1. History of PET and PET/CT

Year	Milestone(s)	Investigator(s)
1951	First use of NaI probe for brain PET	W Sweet, G Brownell
1963	First description of Radon equations for image reconstruction	AM Cormack
1973	Description of CT scanner	GN Hounsfield
	First PET tomography	ME Phelps
1977	Synthesis of C-14 deoxyglucose	L Sokoloff
1978	First commercial PET scanner	
	First bismuth germanate (BGO)-based scanner	C Thompson
	Synthesis of F-18 fluoro-deoxyglucose (FDG)	T Ido
1984+	Commercial cyclotron development	
1986	Present synthesis of FDG	K Hamacher
1997	FDA approval of FDG as a radiopharmaceutical	
1999	Lutetium orthosilicate (LSO)	
	Medicare reimbursements for staging NSCLC, SPN, colorectal cancer, HD and NHL, melanoma, hibernating myocardium and TLE	
2000	PET/CT	
2002	Health Technology Board for Scotland recommendation: FDG-PET	
	HD restaging after ABVD, and in NSCLC, in CT N negative disease	

Logistics: Clinical

In this brief review, there will be no address in any detail about the complex logistics required for setting up a PET/CT scanning service, the supply of FDG (off-site or on-site), the rapidly evolving protocols in respect to CT oral and IV contrast, the relative merits and imperfections of SUV analysis, motion correction issues, list mode acquisition advantages, etc. Many of these are dominated by local circumstances and are also subject to much work in progress. Instead we will focus on the clinical environment that will permit a good clinical PET/CT service to evolve. Foremost and above all is the accuracy and extent of relevant clinical information available prior to scanning. Table 2 describes simple but fundamental aspects of history taking. Clinical details should be available prior to scanning and be used in the overall process of study analysis and interpretation.

Table 2. Assemble Clinical Details Prior to Scanning

Surgery: When?	Chemotherapy: Started when?
Surgery: Where? (R/L)	Chemotherapy: Stopped when?
Surgery: What type?	Biopsy sites: Where and when?
Tubes: (e.g. tracheostomy, Hickman lines, etc.)	Parallel pathologies: (e.g. diabetes, infection, thyroid, cardiac, soft tissue, etc.)
Recent events: (e.g. trauma, fracture, palpable, abscess, immunocompromise)	General nursing aspects: (e.g. assisted walking, crutches, etc.)

New tracers

The development of new tracers is paramount for the future of nuclear medicine as we know it. This will, however, not take place on a significant scale unless the issues of cost and registration are addressed and solved.

There is, to some extent, an inherent conflict in the field in that much of the novel effort evolves around the design of ever more specific molecules for the study of specific signals (see all the literature on molecular imaging), and yet the gain in specificity can only be at the cost of a reduction of the population to be studied usefully. This in turn reduces the marketability of such compounds, because their registrations (at least in Europe and the USA) have reached prohibitive levels.

The success of FDG is the result of its unusual but favorable properties: relative ease of production

and distribution, reasonable unit cost of the end product, and high image contrast for a very wide range of pathologies (majority of cancers) as well as proven utility in non-cancerous conditions. It will not be easy to find another successful molecule with similar academic, clinical and commercial appeal.

The above considerations explain why much effort has been placed in the development of new F-18- labeled ligands, new solid phase technology, automated radiochemistry, etc. Whilst many signals can be addressed with potentially available F-18-labeled ligands, it is likely that more generic biological signals (such as angiogenesis and apoptosis) will lead to tracers with commercial viability. Table 3 lists a number of such ligands - not an exhaustive list. Much hope is nevertheless also placed in ligands for the CNS (ligands for brain tumors and an F-18 DOPA ligand - an Alzheimer plaque ligand) and for the ultimate successful visualization of the atheroma plaque.

Table 3. Potential F-18-Labeled Ligands

Ligand	Author name, city
FE-CIT - dopamine transport	Mitterhauser et al, Vienna
5-HT1A - serotonin receptor	Chin et al, Bethesda
5-HT1A - serotonin receptor	Vandecapelle et al, Ghent
n.c.a Flumazenil - benzodiazepine receptor	Krasikova et al, St Petersburg
FFMZ - benzodiazepine receptor	Wadsak et al, Vienna
Altanserin - 5HT2A receptor	Frokjaer et al, Copenhagen
Fallypride - D2 receptor (extrastriatal)	Landvogt et al, Mainz
Fluorocholine	Schmid et al, Zurich
Fluoroethyltyrosine	Poepperl et al, Munich
Fluoro 2 methylphenylalanine	Kersemans et al, Gent
2-Nitroimidazole analog (Hypoxia)	Hakamatsuka et al, Sendai
FPyBrA (oligonucleotide labeling)	Dolle et al, Orsay
4-Anilidopiperidines (mu-opioid receptor)	Henriksen et al, Munique
2-Deoxy-2 fluorouridine (proliferation)	Oh et al, Seoul

Table derived from the source.

If we define a clinical tracer as one that will enable us to investigate significant numbers of patients, then C-11-labeled tracers will never comply with this requirement. However, much will be learned from C-11 ligands, and they may indeed point and lead the way to the discovery of other new and clinically relevant F-18 ligands. Generator-based positron emitters, such as Ga-68, have indeed a

future, yet to be fully explored.

The clinical role of FDG in oncology

Today, despite the sophisticated and ever-increasing map of pathways of cancer expression, it is a totally nonspecific tracer (FDG) that is giving us a handle in PET/CT.

In very general terms, the mechanisms that pre-empt over the transport, uptake and retention of labeled FDG in cancer cells include overexpression of membrane glucose transporter proteins/glycoproteins, increased glucose transport, increased glycolysis, increased hexokinase, and decreased glucose-6-phosphatase.

Much is now known in this respect - several glucose transporters have been identified and these are known to be expressed to different degrees in different tumors. However, a detailed description of what is known falls outside the scope of this overarching review of PET/CT in oncology.

Use of PET/CT to assess early response to novel therapies

PET/CT today is indeed an essential tool in the management of patients with cancer. It offers us an objective assessment of therapy response, which is now an extended role for this relatively new imaging modality. Figure 1 shows an example of a patient with a germ cell tumor with clear abdominal FDG-avid lymph nodes. Three days after a single dose of carboplatin, there was a total shutdown of the glucose transporters of these FDG-avid nodes. This was the first time we showed that response occurred within 3 days. A nonspecific FDG-avid node was seen here, which is often observed with these patients. There was a lot of discussion about whether carboplatin would act so rapidly, and PET/CT seems to demonstrate that this response is indeed very rapid. Whether these cells still remain viable is an issue which will need to be followed up. Figure 2 shows a patient with altered distribution of FDG. There is a lot of activity in vessels, especially in the arteries. This patient had giant cell arteritis. In giant cell arteritis there is often some issue about circulating B lymphocytes. Many of these patients are subject to a number of cycles of steroid therapy and they may develop refractory symptomatology. Therefore, to deplete patients of their B lymphocytes is a therapeutic option; this was done here with anti-CD20

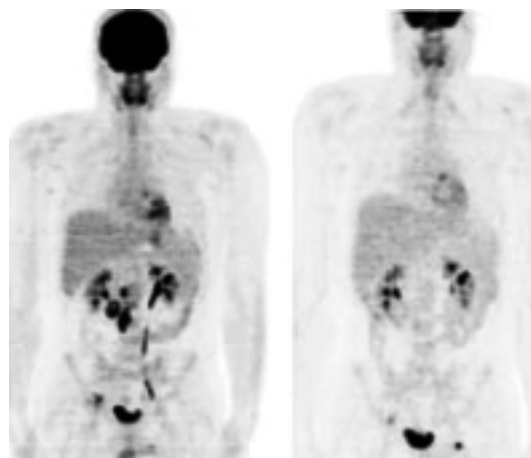


Fig. 1 A germ-cell tumor with clear abdominal lymph node FDG-avid disease.

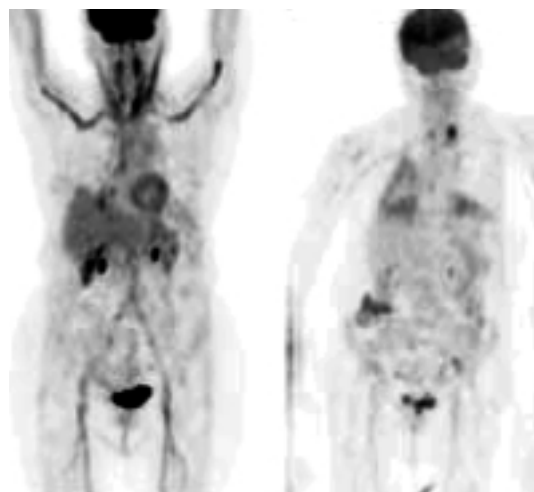


Fig. 2 Giant cell arteritis showing altered distribution of FDG.

monoclonal antibody (MoAb). This case demonstrated a clear response to the medication. However, this kind of treatment may lead to respiratory distress. In fact, the patient took a long time to recover, but the point is made that PET/CT is a tool that you can use to assess early response to novel therapies.

Indications for PET/CT in oncology

In general terms and as we see it in late 2004, PET/CT is still not a first-line investigation for the diagnosis of cancer. In most institutions, PET/CT is being used after the patient has presented to a hospital and been submitted to a whole battery of clinical,

laboratory-based and conventional imaging-based studies.

In most circumstances PET/CT is called upon in oncology to assess the extent and severity of disease (i.e., in the context of staging and re-staging) and in the context of treatment response. With regard to the former, the authors of a paper published in German in 2003 suggested that combined PET/CT is superior to MR in most tumor staging, and described PET/CT as a first-line tool for whole-body tumor staging. Across T, N and M staging, PET/CT outperformed whole-body MR. With regard to the latter, treatment response would often require a baseline investigation, and this algorithm is still subject to significant discussion amongst referring physicians and nuclear medicine/radiology practitioners.

A one-year clinical experience of PET/CT (in 2002) in our group showed that the impact of PET/CT has altered staging in 39% of cases (25% were upstaged and 14% were downstaged). The important point to make is that, in our institution, the patients are still very often referred last when all other investigations have been performed. It will take quite some time, at least in UK and Europe, before PET/CT will become the first port-of-call in a variety of disease entities. We strongly believe that this will occur over the next 5 years or so.

PET/CT informs radiotherapy planning. However, PET/CT is not an appropriate technology for screening asymptomatic populations - in general and with few exceptions (such as mammography) imaging technologies are not suitable for screening.

Below we briefly discuss the main clinical indications for PET/CT in oncology.

Brain tumors

PET/CT is often not a first tool for the investigation of a patient suspected to have brain tumor. Most of the time, referrals arise from a series of failed initial investigations. Perhaps the most direct referral for a suspected brain tumor arises from those patients suspected to have paraneoplastic syndrome where PET/CT is used to localize a tumor. For appropriately selected patients, this is a most useful indication. Figure 3 shows a patient who had a 3-year history of cognitive decline with positive CSF antibodies, negative antineuronal antibodies. A brain tumor was found. Even in the days when we had PET only, this seemed to be interesting. There was

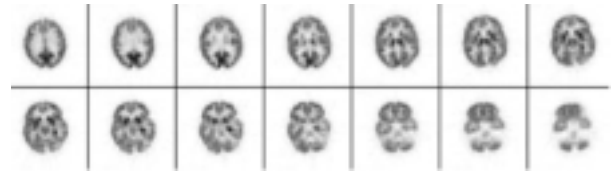

Fig. 3 Case: A brain tumor with 3-year history of cognitive decline.

another case of a 39-year-old woman with an undiagnosed brain stem encephalopathy with positive anti-CD20 MoAb, and the diagnosis of paraneoplastic syndrome was proposed. There were a number of symptoms. The patient had been investigated for almost 2 years with all sorts of cross-sectional imaging modalities, and it was a PET-only study which clearly showed the abnormality.

PET/CT is also used to grade tumors at presentation, report a high-grade evolution, and distinguish between recurrence and scarring after treatment. Patients with high-grade cancer and high FDG retention will have a poorer prognosis, but more useful is the information that a high-grade tumor which shows poor FDG uptake is often associated with a better outcome.

With the increasing availability of ¹⁸F-FLT, this ligand may be useful when the blood-brain barrier is disrupted and tumors are difficult to be identified on FDG imaging. As a marker of proliferation, FLT may have a significant role to play. ¹⁸F-DOPA is a ligand that may become routinely available with significant potential for further tumor characterization and investigation of the dopamine transporter status.

Head and neck cancers

PET/CT is possibly the superior imaging modality for the initial staging and diagnosis of primary and recurrent cancer of head and neck. Here PET/CT has made a major difference in respect to PET-only imaging; the complex anatomy and distribution of muscle and nodes in this region requires the most accurate co-registration in a single setting. PET/CT is the investigation of choice for these patients (Figs. 4 and 5). When PET and CT were performed separately, CT might have become the only study performed, in that PET was not going to increase the sensitivity of detecting primary head and neck tumors. Now with PET/CT this has ceased to be the case - PET/CT should be the first port of call at pre-

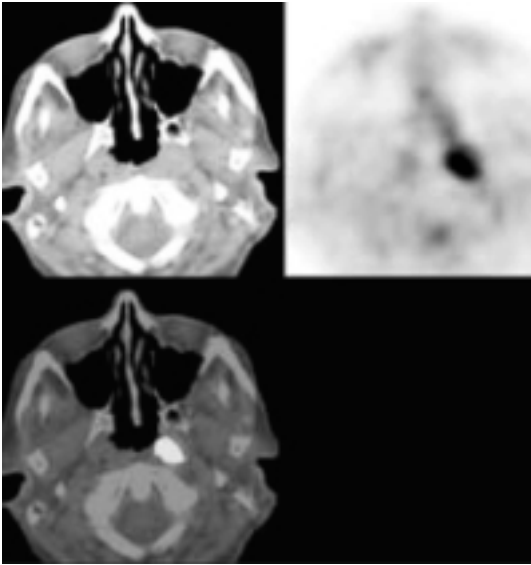


Fig. 4 Case: left nasopharyngeal carcinoma.




Fig. 5 Exquisite detail can be offered with PET/CT, and the primary laryngeal carcinoma tumor is clearly visualized.

sentation, as the combined modality will have improved specificity.

PET/CT is best at N staging and M staging in these patients, and it is clearly superior to CT and MR in this context. PET/CT will also be used to import data to the RT and IMRT (intensity-modulated radiotherapy) treatment plans. From our limited success with PET/CT in the head and neck, we looked at a comparative series with MR. There is no doubt we get better images; very small tumors can be beautifully localized. To summarize the data: (1) PET/CT was better for nodal disease; (2) no imaging modality detected micrometastases; and (3) PET/CT was better than MR for local recurrence, and possibly better than CT, although we still had a reasonably high false-positive rate.

Thyroid cancer

It now has been shown amply that PET/CT is able to demonstrate FDG-avid thyroid cancer. The issue at stake is the clinical impact of this finding. There is no role for PET/CT for T staging. In the thyroid the indications are limited to the assessment of patients with (1) elevated TG levels and negative iodine scans; and (2) tumor recurrence (occasionally) of medullary carcinoma. PET/CT is not indicated routinely for patients with positive I-131 scans and positive TG levels. We do not propose to use PET/CT to image patients with goiter. Sometimes in incidental cases we see FDG-avid thyroid nodule such as the gastric FDG uptake in a patient with some gastric symptoms, who in fact had rather limited disease in the mucosa of the stomach. In high-risk cancers there may be a limited role for PET/CT as a prediction of tumor response to treatment (e.g. retinoic acid), and possibly the role can be extended to those few patients amenable to a local resection of a single mass (Fig. 6).

Parathyroid cancer

There is presently no clinical indication for PET/CT imaging in parathyroid disease. Brown tumors are FDG-negative.

Lung cancer

PET/CT has shown cost benefit in the management of non-small-cell lung cancer (NSCLC), and many studies have shown its benefit in sparing unnecessary surgery, in upstaging disease both for N

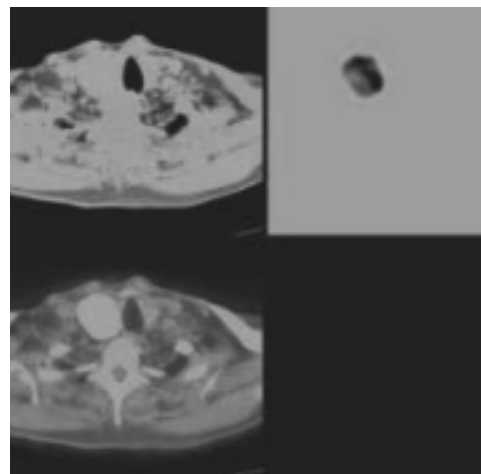


Fig. 6 A patient with a goiter.

and M staging. PET/CT is rapidly becoming the first port of call for T staging. With the exception of bronchioloalveolar cancers, most lung cancers show significant uptake of FDG. PET/CT is also a most useful investigation in solitary pulmonary nodules but pathology such as sarcoidosis, granulomas in general, and tuberculosis are also known to take up FDG and must be taken into account when differential diagnosis is required. It is likely that a contrast-enhanced PET/CT will become the first port of call for the initial staging of a patient presenting with a clinical suspicion of a lung cancer. Figures 7 and 8 demonstrated a 75-year-old male with hemoptysis. At bronchoscopy the patient showed abnormal mucosa at the lingula, and the cytology suggested a squamous cell carcinoma, but histology showed severe dysplasia. On fluorescence assessment, the lingular abnormality was seen but there was also an abnormal mucosal lining at the left main bronchus. PET/CT showed no uptake in the lingula or the left main bronchus but showed uptake in the apicoposterior bronchus in the left upper lobe and this was confirmed histologically. So, fluorescence here got it wrong. In PET/CT study, a primary tumor (Fig. 7) and a very small 7-mm precarinal lesion (Fig. 8) were beautifully localized.

There are three important statements arising from the peer-reviewed literature: PET/CT is effective; safe; and cost-effective - it saves unnecessary surgery in one out of five patients.

Esophageal cancer

Tables 5, 6 and 7 summarize some of the avail-

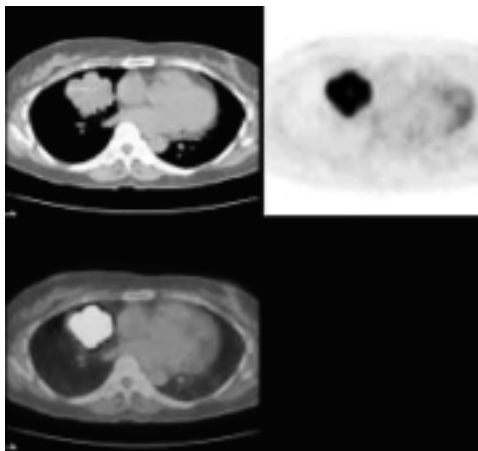


Fig. 7 A primary tumor of non-small-cell lung cancer.

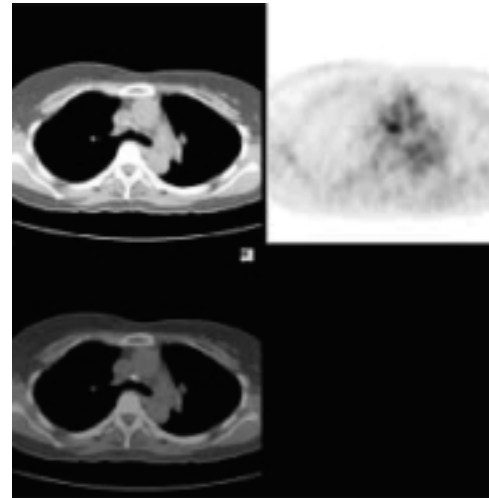


Fig. 8 A 7-mm precarinal lesion in PET/CT.

able evidence. In the esophagus, the clinical indication for PET/CT are (1) for staging with curative intent; (2) to assess disease recurrence in previously treated patients; and (3) to assess treatment response in a trial context. We know that the number of positive lymph nodes has a significant impact on survival. Therefore the more nodes you see the worse the prognosis; here PET/CT may be quite interesting. And we know that PET will do well to distinguish responders from non-responders.

Table 5. FDG-PET in Esophageal Cancer: Incremental Value over CT

	Sensitivity	Specificity	Accuracy
FDG-PET	80%	95%	86%
CT	68%	71%	73%
PET for primary	99%		

N = 109; 151 scans (staging, 67; chemotherapy follow-up, 66; recurrence post-surgery, 18); PET impact on patient management, 14%. Data derived from Yeung et al, *Clin Pos Imaging* 1999;2:255-60.

Table 6. Metastases to Regional Lymph Nodes in Esophageal Squamous Cell Cancer: CT Versus FDG-PET for Pre-Surgical Detection

	Sensitivity	Specificity	Accuracy
CT	11%	95%	83%
FDG-PET	30%	90%	82%

N = 81. Data derived from Yoon et al, *Radiology* 2003; 227: 764-70.

Table 7. Esophageal Cancer: Response to Therapy

	FDG uptake* in chemotherapy patients [‡] (N = 40)	FDG uptake in chemotherapy+radiotherapy patients [†] (N = 27)
Responders	↓ 54%	↓ 72%
Non-responders	↓ 15%	↓ 22%

* PET at baseline and day 14: sensitivity, 93%; specificity, 95%.

† Weber et al, *J Clin Oncol* 2001;19:3058-65.

‡ Brucher et al, *Ann Surg* 2001;233:300-9.

Lymphoma

The following list summarizes the main advantages of PET/CT in the investigation of Hodgkin's disease (HD) and non-Hodgkin's lymphoma (NHL) patients. PET/CT now has a major role to play in the management of these patients in (1) diagnosis of disease in CT normal-sized lymph nodes; (2) primary staging of HD and NHL; (3) better than CT in nodal and extra-nodal disease; (4) upstaging in about 40% of all patients; (5) variable FDG uptake in MALT lymphoma; (6) controversy in bone marrow staging; (7) better than CT at post-therapy evaluation; (8) positive post-treatment PET equal to poor prognosis; and (9) in aggressive HD and NHL, a scan performed post one cycle of chemotherapy is predictive. A baseline study is often useful to monitor treatment response and PET/CT is helpful for the persistent mass after therapy, in order to differentiate fibrosis from viable tumor. PET/CT is highly sensitive, is an important tool for treatment response assessment and is now often used in the longitudinal monitoring of many patients presenting with lymphoma. PET/CT detects occult disease not seen on conventional imaging: in HD a negative study has high predictive value for a good prognostic outcome; in NHL a positive scan is highly predictive of recurrence. PET is the best technology to identify patients for salvage chemotherapy.

PET/CT is less sensitive in low-grade lymphomas and hence may not identify all lesions seen on conventional imaging. A baseline study will, however, be very useful in supporting a diagnosis of transformation into a higher grade malignancy (Fig. 9 and 10).

Pancreatic cancer

There are quite a lot of data in the literature showing the sensitivity and the reasonably good specificity for PET/CT in the pancreas. The value of

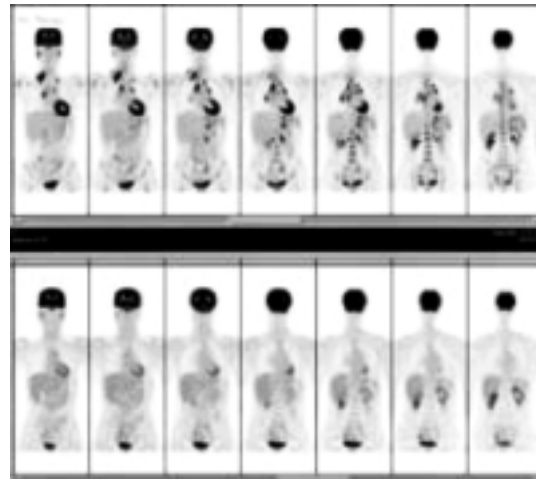


Fig. 9 A patient with Hodgkin's disease showing complete response to therapy.

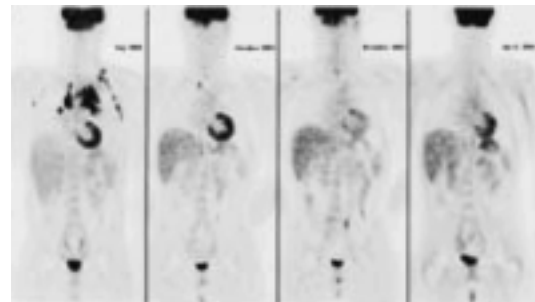


Fig. 10 Treatment follow-up in lymphoma over a 1-year period. Many of these patients will receive more than a single PET/CT study.

FDG-PET in patients with cystic tumors of the pancreas was shown in a study of 17 patients with malignant tumors, 16 positive for FDG (where positivity was defined as an SUV > 2.6, with a classification of benign lesions as SUV < 2.6). The study showed great superiority of PET results over CT. In one of our own studies, in relation to spiral CT, we upstaged disease in 26% of patients in a small sample of 29 patients with pancreatobiliary carcinoma (unpublished data).

Colorectal cancer

In colorectal cancer, PET/CT has proven clear utility in (1) assessment of recurrent disease prior to surgical removal of metastasis with curative intent; (2) not indicated routinely for diagnosing the primary and for assessing tumor response, but in a trial

context we do look at tumor response; and (3) uncertainty of the role of PET/CT in polyp assessment.

PET/CT has a recognized place in the management of colorectal cancer patients once a primary assessment and the diagnosis have been established. PET/CT is best at highlighting recurrence; it is exquisitely sensitive to the detection of liver deposits (Fig. 11); it is clearly useful in the staging and restaging process. While only subtle abnormalities were seen in the CT of the patient, PET/CT in Figure 11 showed multiple liver deposits. The patient was proposed to have removal of a single deposit, but instead was upstaged and saved from unnecessary surgery.




Fig. 11 Unequivocal liver lesions seen on FDG-PET in the context of an equivocal CT.

In a prospective study from December 2003 onwards, we collected 45 consecutive patients and looked at ultrasound and CT (chest, abdomen, pelvis) for initial staging (submitted for publication). FDG-PET provided different information to CT/MR in 24/45 patients and altered management in 35%. Overall, FDG-PET outscored CT for sensitivity, specificity, positive and negative predictive values and accuracy. A vast body of literature confirms this. A meta-analysis from Dietlein's group was performed on data from over 1,000 patients. With good levels of evidence (IIa) by HDA-type analysis, the addition of PET changed management in this meta-analysis in 34% of all patients. PET/CT is more sensitive than CT, both in node involvement and in the assessment of liver involvement prior to possible metastasectomy. PET/CT spares unnecessary liver surgery and is a cost-effective technology in this setting.

Indications for PET/CT in other cancers

In a variety of other settings, PET/CT is playing an increasing role. This applies to breast cancer, where restaging is an increasing source of referrals. PET/CT should not be used for axillary staging or for primary breast tumor detection. PET/CT is indicated for (1) chemotherapy response assessment as part of a trial; (2) evaluation of brachial plexus damage; (3) diagnosis of restaging in disease recurrence. In melanoma, the indications were (1) staging in Breslow's > 1.5 cm; (2) nodal staging; (3) clarification of abnormal radiological findings; (4) restaging prior to surgery; and (5) treatment monitoring. In testicular cancer, PET/CT is indicated for (1) assessment of recurrent disease from seminomas and teratomas; (2) assessment of residual mass; and (3) increasingly, therapy response. PET/CT has useful information to bring to the investigation of adrenal masses; to GIST tumors; to multiple myeloma; to germ cell cancers, where early response to treatment has been documented, etc. On the other hand, PET/CT appears less useful in neuroendocrine tumor and in prostate cancer.

Other Indications for PET/CT

Non-cancerous conditions

It is also now perfectly clear that PET/CT is having a useful role in a number of non-cancerous conditions.

These range from the investigation of cerebral metabolism to the confirmation of infection/inflammation. Plaques of atheroma have been shown, and patients with arteritis (Fig. 12) have been successfully and usefully investigated. These indications and their relevance fall however outside the scope of this review.

Skeletal imaging

PET/CT has a great future in the imaging of the skeleton - the main ligand will be ¹⁸F-fluoride.

The ¹⁸F - fluoride ion has been available for skeletal scintigraphy since the 1960s but it has only now gained an established clinical place. ¹⁸F-fluoride PET/CT bone scanning is more sensitive than methylene diphosphonate (MDP) bone scans and will supersede MDP scintigraphy if it can demonstrate cost effectiveness. Scans are fast, can be performed earlier than MDP after patient administration

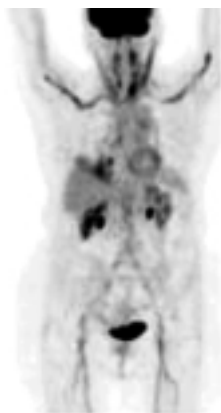

Fig. 12 Typical features of arteritis: the image is, in essence, diagnostic. Two weeks after steroids, the scan reverted to normal.

(at 1 hour) and have the inherent advantage of combined anatomical as well as metabolic information. Whether PET/CT skeletal scintigraphy will be superior to STIR MR sequences will need to be demonstrated.

Sclerotic lesions may escape PET detection since ¹⁸F-fluoride may exhibit less binding to these lesions (Fig. 13).

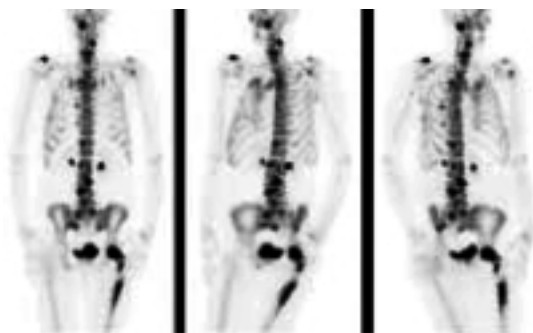


Fig. 13 A typical ¹⁸F-fluoride study with multiple skeletal deposits.

Conclusion

PET/CT has a major impact in the investigation of patients with cancer. It has changed dramatically the management of numerous cancers and its impact has been felt worldwide. PET/CT will be used with increasing frequency, indications will be further

refined and PET/CT will become progressively used as a surrogate marker for disease response. Novel ligands, labeled with F-18, will further increase the clinical utility of this technology. New training programs will need to be established so that the full benefit of this technology will emerge from within a true multidisciplinary approach. This will become increasingly relevant as the new multislice PET/CT scanners (16 slices or plus) will further influence the new imaging protocols.

REFERENCES

1. Abstracts of the Annual Congress of the EANM, Helsinki, 2004. *Eur J Nucl Med Mol Imaging* 2004;31(Suppl 2).
2. Lardinois D, Weder W, Hany TF, et al. Staging of non-small-cell lung cancer with integrated positron-emission tomography and computed tomography. *N Engl J Med* 2003;348:2500-7.
3. van Tinteren H, Hoekstra OS, Smit EF, et al. Effectiveness of positron emission tomography in the pre-operative assessment of patients with suspected non-small-cell lung cancer: the PLUS multicentre randomised trial. *Lancet* 2002;359:1388-93.
4. Verboom P, van Tinteren H, Hoekstra OS, et al. Cost-effectiveness of FDG-PET in staging non-small cell lung cancer: the PLUS study. *Eur J Nucl Med Mol Imag* 2003; 30:1444-9.

Selected further reading

- Atlas of PET/CT. In: Ell PJ, Gambhir S, Eds. *Nuclear Medicine in Clinical Diagnosis and Treatment*, 3rd Edition. Elsevier, 2004.
- Boucher L, Rodrigue S, Lecomte R, Benard F. Respiratory gating for 3-dimensional PET of the thorax. Feasibility and initial results. *J Nucl Med* 2004;45:214-9.
- Bradley JD, Perez CA, Dehdashti F, Siegel BA. Implementing biologic target volumes in radiation treatment planning for non-small-cell cancer. *J Nucl Med* 2004;45(Suppl 1):96S-101S.
- Gambhir SS, Czernin J, Schwimmer J, et al. A Tabulated Summary of the FDG PET Literature. *J Nucl Med* 2001;42(Suppl 5):1S-93S.
- von Schulthess GK. *Clinical Molecular Anatomic Imaging*. Lippincott Williams and Wilkins, 2003.