

## Trapezoidal Titanium Cage in Anterior Cervical Interbody Fusion: A Clinical Experience

Chi-Chien Niu, MD; Lih-Huei Chen, MD; Po-Liang Lai, MD; Tsai-Sheng Fu, MD;  
Wen-Jer Chen, MD, PhD

**Background:** Use of autogenous bone grafting taken from anterior iliac crest for anterior cervical interbody fusion has been the “gold-standard” for decades. Substitutes for autogenous bone graft continue to be sought to avoid potential donor site morbidity. A titanium-alloy square-shaped hollow cage was applied to facilitate the process of fusion as a bone graft substitute, then assessed in this retrospective clinical study.

**Methods:** From July 2000 to July 2001, sixty-three discs from fifty-four patients were selected to receive this cage for one or two segments of the cervical spine for anterior cervical interbody fusion. The Japanese Orthopedic Association (JOA) score and Odom's criteria were used to measure the clinical outcome. Postoperative radiographs were analyzed for graft dislodgement, loss of anterior and posterior disc heights, maintenance of lordosis correction, and status of fusion between the cage and endplates to assess their suitability as a grafting substitute.

**Results:** Eighty-seven percent of patients exhibited satisfactory clinical outcome. Successful fusion was obtained in ninety point five percent of operated discs. Partial cage dislodgement was observed in four point eight percent of discs and caused no adverse symptoms. The mean collapse of the anterior and posterior disc heights were 1.73 mm and 0.91 mm, respectively. Moreover, the mean loss of lordosis correction was 2.75°.

**Conclusions:** Based on this primary clinical experience, the trapezoid-design, titanium-alloy cage provided adequate mechanical support and stability in the disc space and an excellent fusion result without significant subsidence of disc height or any other complications.

*(Chang Gung Med J 2005;28:212-21)*

**Key words:** cervical spine, interbody fusion, cage, titanium alloy.

Since cervical spine degeneration originates from the vertebral disc,<sup>(1)</sup> most pathologies of cervical spondylosis occur in proximity of the disc, including disc herniation, osteophyte hypertrophy at

endplates or uncovertebral joints. The anterior approach to the subaxial cervical spine for discectomy and interbody fusion has become more popular than the posterior approaches. Besides the advantage

---

From the Department of Orthopaedic Surgery, Chang Gung Memorial Hospital, Taipei.

Received: Sep. 30, 2004; Accepted: Mar. 9, 2005

Address for reprints: Dr. Chi-Chien Niu, Department of Orthopaedic Surgery, Chang Gung Memorial Hospital, 5, Fushing Street, Gueishan Shiang, Taoyuan, Taiwan 333, R.O.C. Tel:886-3-328-1200 ext. 2163; Fax:886-3-327-8113; E-mail: niuchien@adm.cgmh.org.tw

of directly decompressing the pathology, indirect decompression by restoring the disk space height could be achieved through an anterior graft placed in the disc space. However, the complications of pseudarthrosis, graft breakage or dislodgement, and disc space collapse complicate the clinical results.

Although successful fusion is achievable through autogenous bone graft, graft procurement from the iliac crest has associated complications. Various studies have reported the incidence of donor site complications to be ten to twentypercent. Donor site pain could persist for over a year in over one third of the patients in a single series.<sup>(2)</sup> Other complications include wound hematoma, infection, iliac crest fracture, visceral herniation, meralgia parasthetica, and cosmetic deformity. Furthermore, the second incision for graft harvesting, even when performed by an experienced surgeon, prolongs surgery by half an hour. Numerous bone graft substitutes have been applied and studied in both humans and animals as potential substitutes for autograft in interbody fusion.<sup>(3-5)</sup>

The criteria required by a supreme bone substitute or device for cervical interbody fusion are the following: providing immediate stability in compression, resisting displacement, minimizing neck pain, maintaining spinal alignment and foraminal height, as well as higher or at least equal fusion success rate and clinical success rate, and obviating complications by using autograft.

This clinical study uses retrospective evaluation to seek an alternative to bone autografts in cervical interbody fusion, namely a titanium-alloy, hollow, and trapezoid-shaped cage (VIGOR™, Central Medical Technologies, Taipei, Taiwan) filled with tricalcium phosphate granules.

## METHODS

Because the National Health Insurance Bureau, Taiwan, R.O.C did not cover the cost for the use of a spacer or cage in either lumbar or cervical interbody fusions during the study period, the patients had to pay for this device. Patients affording and consenting to using this device as graft substitute were selected for the clinical study. In the period July 2000 to July 2001, fifty-seven patients undergoing single level or double level anterior cervical interbody fusion with aforementioned device (VIGOR cage), and fifty-four

patients with a minimum of a twelve month follow-up (for whom complete charts and radiographic records were available), were selected for this study. The follow-up rate was ninety-five percent.

The series comprised of thirty-one men and twenty-three women, with an average age of fifty-three years (range, thirty-five to sixty-six years). Sixty-three discs from the fifty-four patients were treated surgically. Single-level interbody fusion was performed in forty-five patients and double-level fusion was performed in nine patients. The diagnoses for surgery were spondylotic myelopathy in nineteen discs, foraminal stenosis in twenty discs, and herniated intervertebral disc in twenty-four discs. Seventeen patients were smokers and thirty-seven were non-smokers. The patients with vertebral body instability caused by trauma or degeneration and needing augmenting plate fixation, or multiple levels (three or more) of interbody fusion were excluded.

### Surgical procedures

The standard Smith-Robinson anteromedial approach (to the cervical spine) was used. The decompression engaged most of the surgical procedure time. On completion of the discectomy and necessary decompression for the hypertrophic osteophyte (that caused cord or root stenosis at the posterior margin of the endplates and bilateral uncovertebral joints), the upper and lower endplates were prepared by removing only the overlying cartilage and preserving the hardest subchondral bone. The advantage of preserving much of the endplate and filling the disc space with a greater quantity of bone graft should reduce the risk of graft collapse. This leaves the strongest bone adjacent to the implanted graft and requires a precisely cut graft to exactly match the interspace. Accordingly, a flat surfaced bone graft (as horse-shoe shaped iliac crest bone graft) or a trapezoidal shaped cage (as VIGOR cage)

**Table 1.** Odom's Criteria for Clinical Outcome Evaluation

Excellent:	All preoperative symptoms relieved, abnormal findings improved
Good:	Minimal persistence of preoperative symptoms, abnormal findings unchanged or improved
Fair:	Definite relief of some preoperative symptoms, other symptoms unchanged or slightly improved
Poor:	Symptoms and signs unchanged or exacerbated

is preferred.

The size of VIGOR cage is defined by the anterior height of cage; that is, a seven mm cage indicates its anterior height is seven mm. Various sized cage has its own trier. Triers are fitted into the disc space to measure the suitable size of cage. To preserve the endplate, the ten-mm size was never used in asian subjects, except in cases where the modified Smith-Robinson's technique (endplates are removed) was employed. Suitable depth and width in the disc space could be prepared by grinding off the edges of semi-circular concavities in the vertebral bodies above and below the disc space in advance to fit the selected trier and the cage without over-destruction of the endplates. Subsequently, the cage impaction would thus become quick and simple resulting from accurate preparation.


The disadvantage, however, is that the endplate is minimally vascularized and the recipient bed is less vascular. Before insertion of the appropriate-sized cage, a bleeding hole was created in the center of the upper and lower endplates respectively in order to enhance the subsequent osteogenesis process through these holes.

Tricalcium phosphate granules (Osteograft-S, Kyocera Co., JPN) were used as the osteoconductive material to fill in the hollow cavity of this device (Fig. 1). No autogenous bone graft was harvested from the iliac crest of the patients.

Duration of admission, operative time, and estimated blood loss were all recorded. Postoperatively, external immobilization via the Miami cervical collar was used for six weeks to three months. Clinical outcome was assessed based on clinical performance at the final follow-up. An independent observer who did not attend the surgery was asked to record the results independently based on the Odom's outcome classification<sup>(6)</sup> from the chart review. Furthermore, patients were asked to determine scores for neurological function evaluation themselves based on the Japanese Orthopedic Association scoring system (JOA score)<sup>(7)</sup> before surgery, during admission, immediately following surgery, and at the final follow-up. The recovery rate then was calculated using the following equation:

$$\frac{\text{post-op (or final) JOA score} - \text{pre-op JOA score}}{17 - \text{pre-op score}} \times 100 \%$$

Plain anteroposterior and lateral cervical spine



**Fig.1** (A) Diagram of VIGOR cervical spinal cage. The shape is squared and the surface is porous coated and tooth-spiked. (B) The hollow space is filled with tricalcium phosphate granules.

radiographs were obtained before surgery and at 0, 3, 6, 9, 12, 24, and 36 months follow-ups. Lateral stress views in flexion and extension were also taken after six months follow-up. Dislodgement or migration, changes in sagittal Cobb's angle<sup>(8)</sup> following surgery and during follow-up, collapse of anterior and posterior disc heights, and fusion result of interbody grafting by the cage were analyzed based on the radiographic studies. Additionally, the Cobb's angle was measured using the extension lines of the upper endplate of the upper vertebrae and the lower endplate of

the lower vertebrae of the fusion disc. The correctibility of the sagittal lordosis from the cage was defined by the Cobb's angle change between preoperation and immediate postoperation (postoperative Cobb's angle - preoperative Cobb's angle). Furthermore, the loss of sagittal lordosis by the block was defined by the change in the Cobb's angle between immediately post-surgery and final follow-up (postoperative Cobb's angle - final Cobb's angle). Anterior interbody height and posterior interbody height were measured using the lateral radiographs. The anterior interbody height was measured as the

distance between the anterior tips of the upper and lower endplates of the fusion disc. Moreover, the posterior interbody height was measured as the distance between the posterior tips of upper and lower endplates of the disc. Collapse of the disc height offered by the cage was defined as loss of either anterior or posterior interbody height exceeding three mm. Failure of interbody fusion using the device was determined by the presence of a radiolucent line between the upper or lower margins of the cage and endplate, or significant Cobb's angle change in the flexion and extension stress views of lateral cervical spine radiographs. In other words, fusion was determined when neither aforementioned signs were present. An independent observer/ surgeon who did not attend the operation and clinical follow-ups was asked to assess the radiographs independently.

**Table 2.** Criteria Adopted by the Japanese Orthopaedic Association for Evaluation of the Results of Operation for Cervical Myelopathy

---

I.	Upper extremity function
0.	impossible to eat with either chopsticks or spoon
1.	possible to eat with spoon, but not with chopsticks
2.	possible to eat with chopsticks, but inadequate
3.	possible to eat with chopsticks, but awkwardly
4.	normal
II.	Lower extremity function
0.	impossible to walk
1.	Needs cane or aid on flat ground
2.	Needs cane or aid only on stairs
3.	Possible to walk without cane or aid, but slowly
4.	normal
III.	Sensory function
A.	upper extremity
0.	Apparent sensory loss
1.	minimal sensory loss
2.	normal
B.	Lower extremity
0.	apparent sensory loss
1.	minimal sensory loss
2.	normal
C.	Trunk
0.	apparent sensory loss
1.	minimal sensory loss
2.	normal
IV.	Bladder function
0.	complete retention
1.	severe disturbance
(1)	inadequate evacuation of the bladder
(2)	straining
(3)	dribbling of urine
2.	mild disturbance
(1)	urinary frequency
(2)	urinary hesitancy
3.	normal

---

## RESULTS

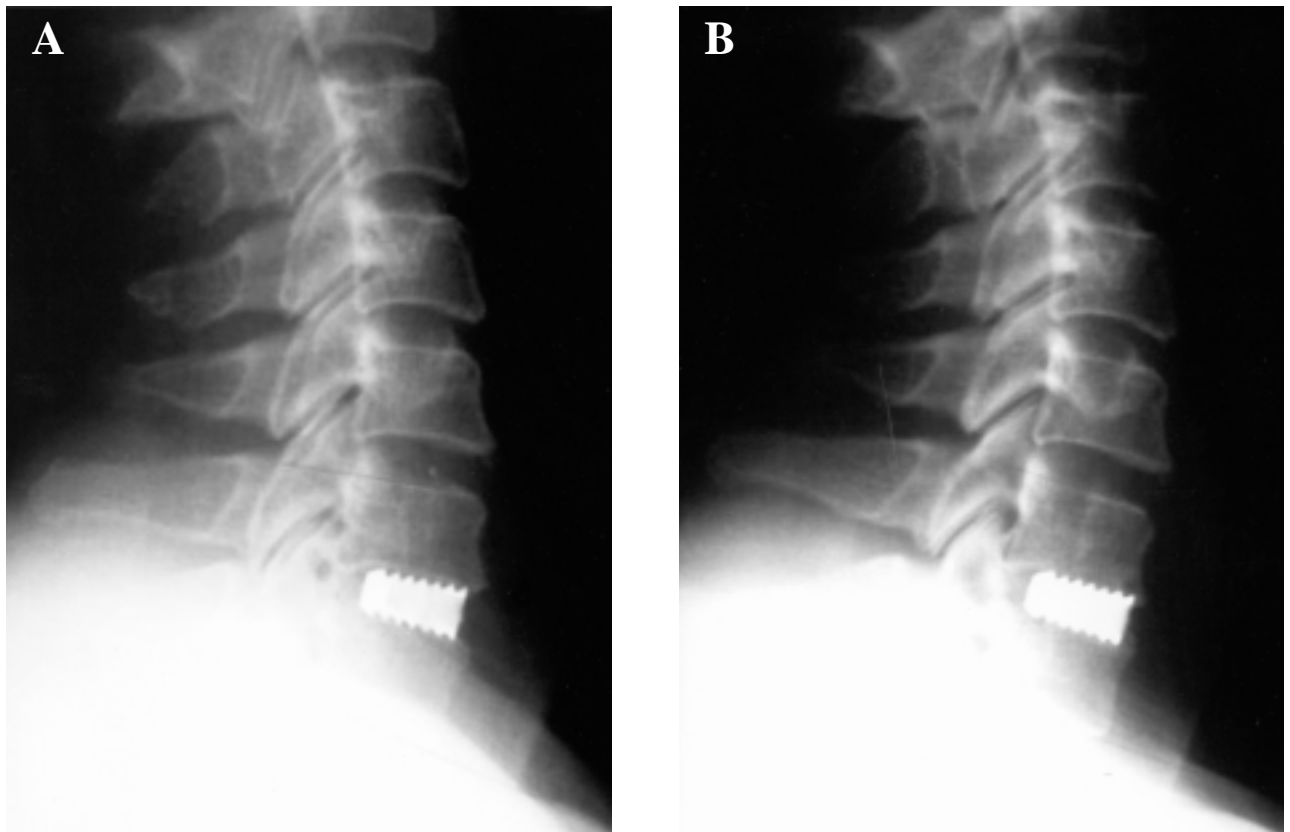
In this series, the mean operative time was 155 minutes (range, 109 to 270 minutes), estimated blood loss was below 50 ml in fifty of the fifty-four patients and 100 to 150 ml in the remaining four patients, and mean admission period was six days (range, five to eight days). Of the sixty-three discs in the fifty-four sample patients, thirty-seven discs used a seven 7 mm thick cage, while the other twenty-six discs used an eight mm thick cage. No wound infection or neurologic aggravation resulting from surgery was noted in the present series, but two patients experienced a temporary grating effect. Fortunately, no other medical complications occurred during the admission of any of the subjects. Postoperatively, the patients wore the Miami cervical orthoses for six to twelve weeks (average, ten weeks).

The mean follow-up period was twenty-six months (range, eighteen to thirty-six months). Based on the radiographic evaluation, the mean preoperative, postoperative, and final follow-up anterior disc heights were 4.33 mm (range, two to six mm), 7.13 mm (range, six to ten mm), and 5.40 mm (range, five to eight mm). The mean size of collapse in anterior disc height was 1.73 mm (range, zero to four mm). Graft collapse of three mm or more was observed in nineteen percent of cases (twelve of the sixty-three discs). The mean preoperative, postoperative, and final follow-up posterior disc heights were 3.0 mm (range, 1 to 5 mm), 3.39 mm (range, 1 to 7 mm), and

2.47 mm (range, 1 to 4 mm). Furthermore, the mean size of collapse in posterior disc height was 0.91 mm (range, 0 to 4 mm). Additionally, the mean segmental lordosis before surgery was 1.0° (range, -8° to 7°), and the mean postoperative and final segmental lordosis were 5.58° (range, -6° to 8°) and 2.83° (range, -8° to 8°), respectively. The mean loss of lordosis correction was 2.75° (range, 0° to 6°). Mild cage extrusion for a distance of one to two teeth (less than 3 mm) on the cage surface was found only in initial follow-up of three discs (five percent, 3/63). Mild cage extrusion did not progress and did not influence the subsequent fusion result in all three discs. The overall fusion rate was ninety percent (Fig.2). Six discs exhibited a persistent radiolucent line along the upper or lower surface of the cages in contact with the endplates in the lateral radiographs and fusion failure was determined (ten percent, 6/63). Among the six patients involved, four received single-level fusion and two received double-level fusion, three

were smokers and three were nonsmokers. The fusion rates were ninety-one percent (41/45) for the patients who received the cage at a single level, and seventy-eight percent (7/9) for the patients who received the cage at double levels. Furthermore, the fusion rate was eighty-two percent (14/17) among smokers and ninety-two percent (34/37) among nonsmokers.

The evaluated neurologic function revealed that the mean preoperative, postoperative, and final follow-up JOA scores were  $11.7 \pm 2.6$ ,  $13.5 \pm 3.1$ , and  $14.1 \pm 2.5$ , respectively. Furthermore, the immediate postoperative recovery rate was mean thirty-eight point eight percent (range, zero to one hundred percent) and the final recovery rate was mean fifty-one point nine percent (range, zero to one hundred percent). Regarding the clinical result evaluated using Odom's criteria, the outcomes of seven patients were graded as excellent, forty as good, six as fair, and only one as poor. Defining satisfaction as



**Fig.2** (A) Postoperative lateral radiograph of a patient with C6-7 disc herniation grafting by a 8mm cage. (B) One-year follow-up radiograph revealed maintenance of disc height and successful fusion.

either excellent or good the overall satisfactory rate thus was eighty-seven percent (47/54).

## DISCUSSION

Various materials have been used in an attempt to avoid donor site complications by employing autograft in cervical interbody fusion. An animal study by Zdeblick et al.<sup>(9)</sup> demonstrated iliac crest allograft to be inferior to autograft from the same anatomic site. Despite different rates of single-level cervical fusion between both autografts and allografts, considerably more nonunions occurred using the freeze-dried allograft for double- and multiple-level fusions. Despite these findings, some researchers have concluded that banked fibula is as effective as autologous grafts.<sup>(10,11)</sup> Nevertheless, the application of the banked allograft will never become a popular technique owing to the possibility of disease transmission. The xenografts, polymethylmethacrylate (PMMA), and Biocompatible Osteoconductive Polymer (BOP) were all demonstrated to act as a spacer with low osseointegration and high graft-related complications such as graft collapse, extrusion, and adjacent vertebral necrosis.<sup>(12-14)</sup> Owing to the bioactive properties of hydroxyapatite (HA), namely direct bonding to bone and osteoconductive effect on the surface of HA implants, the HA block has also been used in this field. However the brittleness of HA creates difficulties in practical applications.<sup>(15)</sup> These difficulties associated with the above graft substitutes encourage the ongoing development of cage technology.

Shape is also an important consideration in designing the graft substitute for cervical interbody fusion. Reviewing the history of grafting techniques reveals that a cylindrical shaped graft was proposed by Badgley and Bailey, and Cloward; a keystone-shaped graft was described by Simmon and Bhalla; and a horseshoe-shaped graft was reported by Robinson and Smith for cervical interbody fusion.<sup>(16-19)</sup> Using the cylindrical shaped graft as the Cloward's technique is associated with a relatively high rate of collapse of interbody space, which may produce certain degrees of neck and shoulder pain.<sup>(20)</sup> Robinson's technique has become the most popular of these alternative techniques for surgically treating cervical disease.

Interbody fusion cages are being designed in the

quest to achieve immediate and strong anterior column support and interspace structural stability during bone fusion. Cage designs can be further sub-divided into three design groups: horizontal cylinder (such as BAK-C; Sulzer Orthopedics, Baar, Switzerland), box (such as Syncage; Synthes, Bochum, Germany), and vertical ring (such as Harms; Depuy Acromed, Sulzbach, Germany) designs. The horizontal cylinder is designed the same as Cloward's graft, the box and the vertical ring are similar to Smith-Robinson's horseshoe graft. Based on in vitro study that biomechanically compares cervical interbody fusion by cages, tricortical bone graft, and intact motion segment, the box designs have considerably greater segmental stiffness in all directions compared to both the intact segment and tricortical bone graft.<sup>(21)</sup> The horizontal cylinder designs were less stable during flexion, extension, and bending than tricortical bone graft. As for the vertical ring designs, the provided stiffness was markedly greater in flexion and extension, but some cages such as Harms cage had lower rotation stiffness because of the smallness of the endplate-implant contact area compared to the intact motion segment; the flexion stiffness of such designs was also considerably lower than for bone graft. Consequently, the cage designs of box or vertical ring are superior to the cylinder designs for cervical spinal interbody fusion from a biomechanical perspective. In a survey of two hundred and fifty clinically studied cases of cervical cage fusion using five different devices, cylindrical cage (as BAK-C) has also been confirmed to be associated with more significant subsidence than the box-shaped impacted cage.<sup>(22)</sup>

The standard Robinson anterior cervical interbody fusion technique uses tricortical iliac crest bone appositional contact with the endplate. Because the rate of pseudarthrosis appears to be higher than desired, varying from twelve to twenty-six percent.<sup>(23)</sup> To lower the pseudarthrosis rate, Emery et al. modified the Robinson technique by burring the endplates to promote vascularity and bone graft incorporation. However, removal of the endplates would cause significant graft settling.<sup>(25)</sup> Biomechanical tests indicate the importance of preserving the endplates as much as possible to prevent graft subsidence into the vertebral body, especially in patients with poor bone quality.<sup>(26)</sup> Furthermore, since the difference in the hardness between the endplate and cancellous

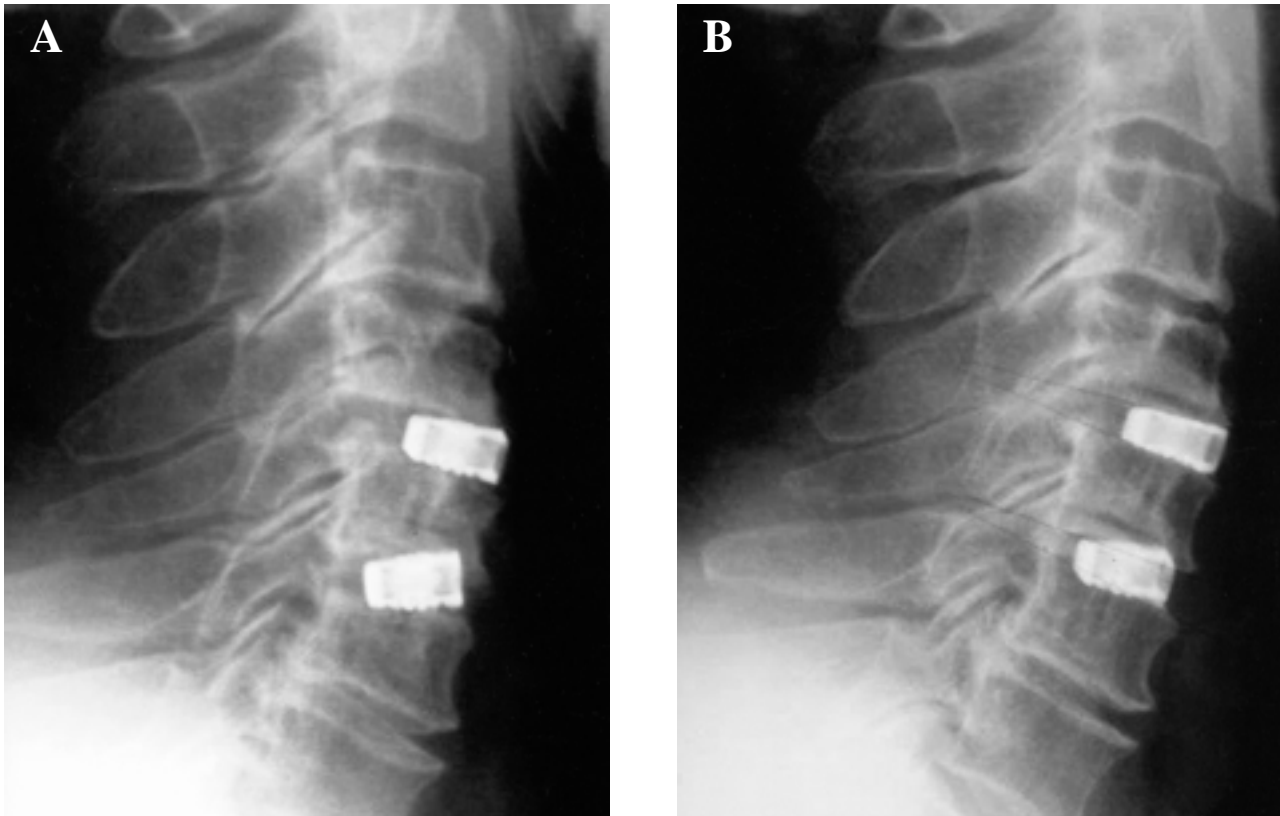
subchondral bone is large, endplate preservation becomes more necessary to prevent the cage sinking into the vertebral body. To preserve the endplate while also achieving a high fusion rate, a central hole was created in the endplates instead of multiple holes to obtain effective vascularity for bone graft osteogenesis and reduce the fracture stresses on the exposed surface area. Greater load to failure of one-hole endplate was demonstrated through the finite element study comparing the potential endplate fracture by replacing one central hole with multiple smaller holes in the endplates.<sup>(26)</sup>

The VIGORTM cervical spinal cage (Central Medical Technologies, Taipei, Taiwan) used in this study is a titanium-alloy (Ti-6Al-4V) trapezoid-shaped hollow device where the endplates are anchored. The trapezoid design is a variation of the box design designed to reduce the subsidence, as discussed above. This device has a trapezoid shape with an anterior slope with an anterior height one mm thicker than the posterior height to better match anterior vertebral geometry and improve lordosis. The horizontal grooves prevent cage migration. It also has a porous (10-400 microns porosity) and nest-like surface design to promote a suitable environment for "bone in-growth". An osteoconductive material, namely tricalcium phosphate in the form of granules, was selected as a graft replacement instead of osteoinductive material as demineralized bone matrix (DBM) or autograft to pack the cages used in patients. Because DBM is not yet available in our institution and autogenous graft from iliac crest was deliberately not selected to avoid donor site complications. In preparing the anchoring endplates, the standard Smith-Robinson technique with endplate preservation was used to prevent cage subsidence and a central bleeding hole was created to promote osteogenesis.

From the follow-up radiographic results, the proposed device and the standard Smith-Robinson's technique with endplate preservation for cage insertion provided sufficient mechanical support to maintain disc height and lordotic sagittal curve in most cases. Although three cases displayed asymptomatic mild cage anterior migration in the early postoperative follow-up, the horizontal groove demonstrated effective prevention of block migration. The causes of anterior mild block migration for these three cases were speculated to be the result of inadequate prepa-

ration of the anchoring bed, for example the space prepared in the deeper part of disc being too small for the block or an oversized block being selected. Four cases had the cage impacted obliquely with asymmetric endplate anchoring. The asymmetric endplate anchoring would result in the block sinking into the cancellous subchondral bone and subsequent interspace collapse (Fig. 3). Fortunately, this unparallel seating of cages does not influence the final fusion results for these four patients. This complication would occur when the targeted disc was located too far from the transverse skin incision, producing an operating angle that was not parallel to the disc direction. The absence of any cases of cage breakage demonstrated that this grafting substitute was sufficiently strong.

Because the success of fusion between the endplates and this titanium cage cannot be determined by the bridging of trabecular bone across the endplates by regular radiographic examination, but alternatively by the criteria of absence of bone rarefaction around the device or segmental instability by significant Cobb's angle change between lateral flexion and extension views. This device achieved a high solid fusion rate (ninety percent). Among the six discs with failed interbody fusion, as defined by persistent rarefaction along the device, three were smokers and the other three exhibited no significant risk factors for nonunion. The stress lateral radiographs failed to reveal definitive instability in any of these cases. There was an opportunity to remove the VIGOR cage from a patient who had received anterior cervical surgery by interbody decompression and fusion in another hospital one year before this admission. Revision surgery of anterior cervical decompression from the cage removal was performed owing to the persistent radiculopathy from the inadequate decompression at the previous operated level. Adequate bone growth had occurred at the porous surface and hole of the removed cage (Fig. 4). The illustration of this removed cage and the satisfactory fusion result in our group demonstrated that the three factors - central bleeding hole at the endplates, porous surface, and artificial osteoconductive graft like tricalcium phosphate granules packed into the cage, successfully promoted interbody arthrodesis. The rate of successful fusion was comparable to the gold-standard graft substitute - autologous tricortical bone from iliac crest. In this series, double-level interbody



**Fig. 3** (A) Postoperative lateral radiograph of a patient with double-level interbody fusion showed asymmetric endplates anchoring the lower cage. (B) Block sinking in cancellous subchondral bone produced interspace collapse, but successful fusion was still demonstrated in the 18-month follow-up radiograph.



**Fig. 4** A photograph revealed adequate bone growth in the hole/hollow and on the porous surface of the removed VIGOR cage.

fusion using a cage could also achieve satisfactory fusion without the need for plate augmentation. Multiple-level fusion using this cage alone is not rec-

ommended presently because clinical literature provides little if not any support for the procedure and the incidence of pseudarthrosis may increase with the number of fusion surfaces.<sup>(27)</sup>

Clinically, an eighty-seven percent success rate and a fifty-two percent final recovery rate of neurological function in terms of the JOA score was achieved by surgery in the present series. No neurological deterioration resulting from surgery was noted. Most patients could ambulate easily using the Miami brace on the second post-operative day.

Learning from previous investigations as discussed above and our study, the preferred box type hollow cage (like VIGOR cage), and the preservation of endplates with the creation of a central hole (like the technique used in the current study), achieved satisfactory fusion result and rigid structural properties. The cage proved to be a reliable alternative to iliac crest bone in cervical interbody fusion. By avoiding the need to harvest bone graft from the



anterior ilium, the operating time could be reduced by at least half an hour, and the patient does not suffer from ilium interference with postoperative ambulation and rehabilitation. The limits of this study include the short follow-up period of only one and a half to three years, and a lack of information regarding the severity of adjacent disc degeneration and durability of this cage. Therefore, a longer follow-up period and a larger sample group of patients are required. Additionally, if the cage for interbody fusion could be made of a material that is radiolucent on a radiograph enabling easier observation of the osteogenesis process, secondly if it was filled with an osteoinductive matrix such as DBM in the holes/hollow of the cage to shorten fusion duration, and cost less, it would be more ideal.

## REFERENCES

1. Clark CR. Degenerative conditions of the spine, differential diagnosis and non-surgical treatment. In: Frymoyer JW, editor-in-chief. *The Adult Spine - Principles and Practice*. New York: Raven Press Co., 1991:1145-64.
2. DePalma AF, Rothman RH, Lewinnek GE, Canale ST. Anterior interbody fusion for severe cervical disc degeneration. *Surg Gynecol Obstet* 1972;134:755-8.
3. Martin GM Jr., Haid RW Jr., MacMillan M, Rodts GE Jr., Berkman R. Anterior cervical discectomy with freeze-dried fibula allograft. *Spine* 1999;24:852-9.
4. Hamburger C, Festenberg FV, Uhi E. Ventral discectomy with PMMA interbody fusion for cervical disc disease. *Spine* 2001;26:249-55.
5. McConnell JR, Freeman BJC, Debnath UK, Grevitt MP, Prince HG, Webb JK. A prospective randomized comparison of coralline hydroxyapatite with autograft in cervical interbody fusion. *Spine* 2003;18:317-23.
6. Odom GL, Finney W, Woodhall B. Cervical disc lesions. *JAMA* 1958;166:23-8.
7. Japanese Orthopaedic Association Society. Scoring system for cervical myelopathy. *J Jpn Orthop Assoc* 1994;68:490-503.
8. Cobb JR. Outline for the study of scoliosis. *American Academy of Orthopaedic Surgery, Instruction Course Lectures*. Vol 5 1948:261-75.
9. Zdeblick TA, Ducker TB. The use of freeze-dried allograft bone for anterior cervical fusion. *Spine* 1991;16:726-9.
10. Rish BL, McFadden JT, Penix JO. Anterior cervical fusion using homologous bone graft: A comparative study. *Surg Neurol* 1976;5:119-21.
11. Young WF, Rossenwasser RH. An early comparative analysis of the use of fibular allograft versus autologous iliac crest for interbody fusion after cervical discectomy. *Spine* 1993;18:1123-4.
12. Rawlinson J. Morbidity after anterior cervical decompression and fusion: The influence of the donor site on recovery, and the results of a trial of surigibone compared to autologous bone. *Acta Neurochir (Wien)* 1994;31:106-18.
13. Madawi AA, Powell M, Crockard HA. Biocompatible osteoconductive polymer versus iliac graft. *Spine* 1996;21:2123-30.
14. Van den Bent MJ, Oosting J, Wouda EJ, Van Acker RE, Ansink BJ, Braakman R. Anterior cervical discectomy with or without fusion with acrylate. *Spine* 1996;21:834-40.
15. Ito M, Abumi K, Shono Y, Kotani Y, Minami A, Kaneda K. Complications related to Hydroxyapatite vertebral spacer in anterior cervical spine surgery. *Spine* 2002;27:428-31.
16. Bailey RW, Badgley CE. Stabilization of the cervical spine by anterior fusion. *J Bone Joint Surg (Am)* 1960;42:565-94.
17. Cloward RB. The anterior approach for the removal of ruptured cervical discs. *J Neurosurg* 1958;15:602-14.
18. Simmon RJ, Bhalla SK. Anterior cervical discectomy and fusion. *J Bone Joint Surg (Br)* 1969;51:225-7.
19. Robinson RA, Smith GW. Anterolateral cervical disc removal and interbody fusion for cervical disc syndrome. *Bull Johns Hopkins Hosp* 1955;96:223-4.
20. Heidecke V, Rainov NG, Marx T, Burkert W. Outcome in Cloward anterior fusion for degenerative cervical spinal disease. *Acta Neurochir* 2000;142:283-91.
21. Kandziora F, Pflugmacher R, Schafer J, Born C, Duda G, Haas NP, Mittlmeier T. Biomechanical comparison of cervical spine interbody fusion cages. *Spine* 2001;26:1850-7.
22. Matge G. Cervical cage fusion with 5 different implants: 250 cases. *Acta Neurochir* 2002;144:539-50.
23. Connolly ES, Seymour RJ, Adams JE. Clinical evaluation of anterior cervical fusion for degenerative cervical disc disease. *J Neurosurg* 1965;23:431-7.
24. Robinson RA, Walker AE, Ferlick DC, Wiecking DK. The results of anterior interbody fusion of the cervical spine. *J Bone Joint Surg (Am)* 1962;44:1569-87.
25. Emery SE, Bolesta MJ, Banks MA, Jones PK. Robinson anterior cervical fusion: comparison of standard and modified techniques. *Spine* 1994;19:660-3.
26. Lim TH, Kwon H, Jeon CH, Kim JG, Sokolowski M, Natarajan R, An HS, Andersson GB. Effect of endplate conditions and bone mineral density on the compressive strength of the graft-endplate interface in anterior cervical spine fusion. *Spine* 2001;26:951-6.
27. Zdeblick TA, Ducker TB. The use of freeze-dried allograft bone for anterior cervical fusion. *Spine* 1991;16:726-9.

## 梯形鈦合金椎籠使用於頸椎前位椎體間融合的臨床經驗

牛自健 陳力輝 賴伯亮 傅再生 陳文哲

**背景：**雖然取自腸骨的自體骨已是施行頸椎椎體間融合所使用的標準植骨。但是由取骨處所衍生出的合併症仍促使不停地尋找其他的代替物。本回溯性研究即在評估一種由鈦合金製造的方型中空椎籠，使用在頸椎椎體間融合的臨床適用性。

**方法：**自2000年7月至2001年7月，隨機收集了54例病人使用此種椎籠進行一節或二節的頸椎椎體間融合。使用JOA評表與Odom's評表來衡量臨床的結果；術後放射線學追蹤檢查前端與後端椎體間高度的變化；對所矯正的頸椎前凸角度的保持能力；與融合成功比率，作為衡量此植骨取代物適用性之依據。

**結果：**臨床滿意結果為87%，融合成功率為90.5%，有4.8%發生椎籠部份脫出現象，但臨床上無症狀。前端與後端椎體間高度平均塌陷1.73毫米與0.91毫米。頸椎前凸角度矯正平均喪失2.75度。

**結論：**本研究顯示此種椎籠確實提供椎體間足夠的結構性支撐與優越的融合成功率，且沒有特殊的合併症的產生。  
(長庚醫誌 2005;28:212-21)

**關鍵字：**頸椎，椎體間融合，椎籠，鈦合金。

---

長庚紀念醫院 台北院區 骨科

受文日期：民國93年9月30日；接受刊載：民國94年3月9日。

索取抽印本處：牛自健醫師，長庚紀念醫院 骨科。桃園縣333龜山鄉復興街5號。Tel.: (03) 3281200轉2163；Fax: (03)3278113；E-mail: niuchien@adm.cgmh.org.tw