

## Choroidal Detachment after Filtering Surgery

Wan-Chen Ku, MD; Yin-Hsin Lin, MD; Lan-Hsin Chuang, MD; Ko-Jen Yang, MD

**Background:** The purpose of this study is to report the treatment and outcome of eight cases of choroidal detachment, which occurred several days to many years after trabeculectomy.

**Methods:** This is a retrospective study of eight cases of choroidal detachment after trabeculectomy with or without cataract extraction reviewed at CGMH, Keelung, from 2002 to 2004. One eye with idiopathic scleromalacia with chronic uveitis and secondary glaucoma, five eyes with primary open angle glaucoma and two eyes with chronic angle closure glaucoma after trabeculectomy were reported. Six of the eight cases developed acute onset choroidal detachment within two weeks after surgery. The other two cases suffered from choroidal detachment many years after trabeculectomy for different reasons. Regarding the types of operation, combined glaucoma and cataract surgery was performed in five cases and intraoperative application of adjunctive mitomycin C was used in two cases. Decrease in vision acuity and varying degrees of eye pain with a flat or shallow chamber were noted in all cases. Associated hypotony was found in six of the eight cases. The treatment included topical cycloplegic corticosteroid and oral corticosteroid.

**Results:** Choroidal detachments were improved or complete resolution obtained after medical treatment for about three weeks to one month in all cases. But persistent poor control of intraocular pressure was found in two cases. Ultrasonography was used as a reliable tool to confirm the diagnosis and resolution of choroidal detachment in cases of blurred fundus examination and synechiae miotic pupil.

**Conclusions:** Choroidal detachment is one of the complications after trabeculectomy. The diagnosis of choroidal detachment can be confirmed most reliably by ultrasonography. Medical therapy is effective for resolution.  
(*Chang Gung Med J* 2005;28:151-8)

**Key words:** choroidal detachment, trabeculectomy, ultrasonography, corticosteroid therapy.

Choroidal detachment (CD) is the accumulation of fluid between the choroid and the sclera.<sup>(1-5)</sup> It is one of the complications after filtering surgery for glaucoma especially in eyes with elevated episcleral venous pressure and aphakia preoperatively.<sup>(4,5)</sup>

Choroidal detachment may occur several days after surgery or it may occur in the late postoperative period due to a variety of causes such as hypotony, ocular inflammation and trauma. Choroidal detachment may be hemorrhagic or non-hemorrhagic.<sup>(6)</sup> The most

---

From the Department of Ophthalmology, Chang Gung Memorial Hospital, Keelung.

Received: Nov. 2, 2004; Accepted: Jan. 13, 2005

Address for reprints: Dr. Wan-Chen Ku, Department of Ophthalmology, Chang Gung Memorial Hospital, No. 222, Maijin Rd., Anle Chiu, Keelung, Taiwan 204, R.O.C. Tel: 886-2-24313131 ext. 2553; Fax: 886-2-24311190; E-mail: susanna@cgmh.org.tw

common manifestation is a non-hemorrhagic detachment of the ciliary body and choroid due to accumulation of serous transudate in the suprachoroidal space associated with postoperative hypotony. We describe eight clinical courses after glaucoma filtering surgery combined with or without a cataract operation, and the treatment results for choroidal detachment.

## METHODS

Details of eight eyes in eight patients with choroidal detachment after filtering surgery at the Chang Gung Memorial Hospital, Keelung, between May 2002 and April 2004 were included in this study. The analysis involved three women and five men with a mean age of 66.3 years (range 43-80). Data that were studied included age, gender, sys-

temic and ocular history, refractory error, operation method, intraoperative and postoperative complications, onset time from surgery to diagnosis of the choroidal detachment, visual acuity (VA) and intraocular pressure (IOP) before and after treatment for the choroidal detachment. Three of the patients had systemic hypertension and diabetes mellitus (cases 3, 6 and 8) and one had a history of branch retinal vein occlusion (case 6). Trabeculectomy combined with cataract extraction and intraocular lens implantation was performed on four of the eight cases. Trabeculectomy combined with cataract extraction without intraocular lens (IOL) implantation was performed in two cases. Trabeculectomy with intraoperative mitomycin C (MMC), as an adjunct therapy, was used for two of the eight cases. The demographic characteristics of all patients with choroidal detachment are shown in Table 1.

**Table 1.** The Demographic Characteristics of Eight Patients with Choroidal Detachment

Case No.	Age/Gender/Eye	Preoperative diagnosis	Previous ocular management before trabeculectomy	Preoperative anti-glaucoma medication	Operation method
1	43/F/R	1. Uveitis with idiopathic scleromalacia 2. Secondary glaucoma 3. Extreme myopia	ECCE	Brimonidine bid Trusopt tid Diamox 1# tid	Trabeculectomy + Mitomycin C
2	74/M/L	1. POAG 2. Cataract	None	Levobunolol bid Trusopt tid Diamox 1# tid	Trabeculectomy  Combined with ECCE
3	80/M/R	Old glaucoma	Unknown	Unknown	1. Trabeculectomy 2. ECCE+IOL implantation
4	54/M/R	POAG	None	Timolol bid	Trabeculectomy + Mitomycin C
5	62/F/R	1. CACG 2. Cataract	Laser iridotomy	Levobunolol bid Rescula bid	Trabeculectomy combined with Phacoemulsification + IOL implantation
6	78/F/R	1. POAG 2. Dense cataract 3. Old BRVO	None	Diamox 1# bid	Trabeculectomy combined with ECCE
7	79/M/R	1. POAG 2. Cataract	None	Timolol bid Trusopt tid	Trabeculectomy combined with Phacoemulsification + IOL implantation
8	61/F/R	1. POAG 2. Cataract	None	Brimonidine bid Trusopt bid Travatan hs Diamox 1# tid	Trabeculectomy combined with Phacoemulsification + IOL implantation

**Abbreviations:** M: male; F: female; R: right; L: left; ECCE: extracapsular cataract extraction; POAG: primary open angle glaucoma; BRVO: branch retinal vein occlusion; IOL: intraocular lens

## RESULTS

All the patients were diagnosed with choroidal detachment by observation of clinical symptoms and via fundus examination, and ultrasonography was used to confirm the diagnosis in cases of blurred view or synchia miotic pupil. All eight cases received medical treatment with topical steroid (predforte qid) and a cycloplegic agent (1% atropine qid), and oral corticosteroid (prednisolone 30 mg/day) was used in five cases immediately after diagnosis of choroidal detachment. Choroidal detachment was resolved successfully after medical treatment of between 2 weeks to 1 month. Post-treatment visual acuity improved in seven of the cases; case 6 patient whose final vision decreased to no light perception. Hypotony was noted when choroidal detachment occurred in five of our cases before treatment. After resolution of the choroidal detachment, persistent hypotony was noted in two cases (cases 3, 4), and four cases (cases 1, 2, 5, 7) had good IOP control with medication. Two cases had poorly controlled IOP even with medication. The visual acuity and intraocular pressure before and after treatment of the choroidal detachment are shown in Table 2 and Table 3.

## CASE REPORT

### Case 1

A 43-year-old woman with a long-standing history of extreme myopia, idiopathic scleromalacia and chronic iritis, with secondary glaucoma, underwent cataract extraction without IOL implantation in her right eye many years ago. Examinations showed a VA of 20/70, C/D ratio of 0.8×0.9 and a progressively deteriorating visual field. She had been treated with brimonidine, trusopt twice daily and oral acetazolamide tablets three times per day for IOP control. However, this treatment appeared to no longer control her IOP by March 2002. The angle showed complete closure and the IOP increased to 28 mmHg in the right eye. So she underwent a trabeculectomy with mitomycin patch and peripheral iridectomy of the right eye.

Postoperative examination showed vitreous prolapse into the anterior chamber with an IOP of 2.1 mmHg and VA of counting fingers at 1m by the next day. However, the patient complained of sudden severe eye pain two days later and an elevated IOP of 22 mmHg with a shallow and inflamed anterior chamber were revealed. Fundus examination showed a bullous peripheral choroidal detachment involving

**Table 2.** Clinical Assessments of Choroidal Detachment Patients

Case No.	VA when choroidal detachment was noted	IOP when choroidal detachment was noted	Onset of choroidal detachment	Ultrasonography Diagnosis	Treatment
1	HM/20cm	22 mmHg	2 days	Hemorrhagic choroidal detachment	Topical steroid + cycloplegic agent; Oral steroid
2	LP(+)	3 mmHg	2 weeks	Annular choroidal detachment	Topical steroid + cycloplegic agent; Oral steroid
3	20/400	3 mmHg	>7 years	Bullous choroidal detachment	Topical steroid + cycloplegic agent
4	20/80	3 mmHg	5 years	Bullous choroidal detachment	Topical steroid + cycloplegic agent
5	CF/10cm	5 mmHg	1 week	Annular peripheral choroidal detachment	Topical steroid + cycloplegic agent; Oral steroid
6	LP(+)	34 mmHg	1 day	Choroidal detachment in temporal area	Topical steroid + cycloplegic; Diamox
7	20/200	8 mmHg	1 week	Annular peripheral choroidal detachment	Topical steroid + cycloplegic agent; Oral steroid
8	15/200	10 mmHg	6 days	Bullous choroidal detachment	Topical steroid + cycloplegic agent; Oral steroid

**Abbreviations:** VA: visual acuity; IOP: intraocular pressure; HM: hand motion; CF: counting figure; LP: light perception

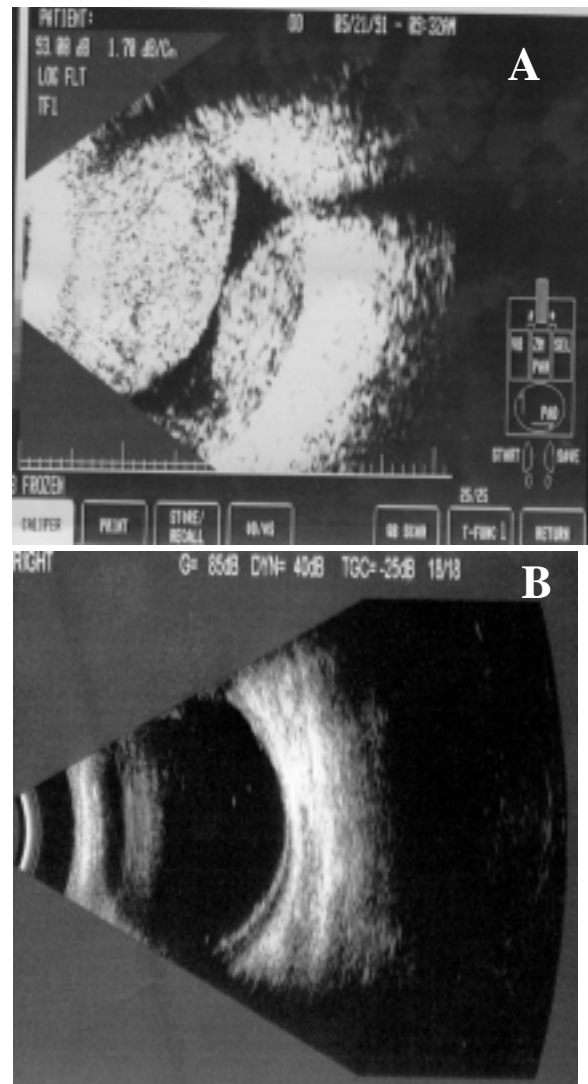
**Table 3.** Clinical Presentations of Choroidal Detachment Patients at the End of the Follow-up Period

Cases No.	Duration of CD	Final VA	Final IOP	Final medication
1	3 weeks	20/80	15	Timolol bid Trusopt tid
2	1 month	HM/15cm	14	Carteolol bid Trusopt bid
3	1 month	20/100	5	None
4	1 month	20/60	5	None
5	2 weeks	20/50	12	Trusopt bid
6	2 weeks	LP(-)	35	Betoptic bid
7	2 weeks	20/100	18	Trusopt bid Timolol bid
8	2 weeks	20/200	22	Cosopt bid Travatan hs Diamox 1# bid

all four quadrants and B-scan echography showed a hemorrhagic component (Fig. 1A). Treatment with topical corticosteroid and a cycloplegic agent were begun first, followed by oral prednisolone 20 mg daily 1 week later because of persistent eye pain. After two weeks treatment, the choroidal detachment resolved (Fig. 1B) and VA recovered to 20/80 with an IOP around 15 mmHg with timolol and trusopt medication.

### Case 3

An 80-year-old male with a long history of right eye chronic angle closure glaucoma and left eye blindness had a medical history that included controlled systemic hypertension and non-insulin-dependent diabetes mellitus controlled by diet and oral hypoglycemics. Trabeculectomy had been performed on his right eye over twenty years previously, followed by cataract surgery with posterior chamber intraocular lens implantation seven years ago. No anti-glaucoma agent was used after trabeculectomy, and the IOP measured between 10 and 14 mmHg and visual acuity between 20/100 and 20/80 during regular follow-ups. However, sudden right eye pain with blurred vision and an IOP that had decreased to 3 mmHg were noted in March 2002. There was no history of head or eye trauma. Slit-lamp examination showed an extremely shallow anterior chamber with peripheral iris-cornea touch and a mild anterior chamber inflammatory reaction. The globe was intact

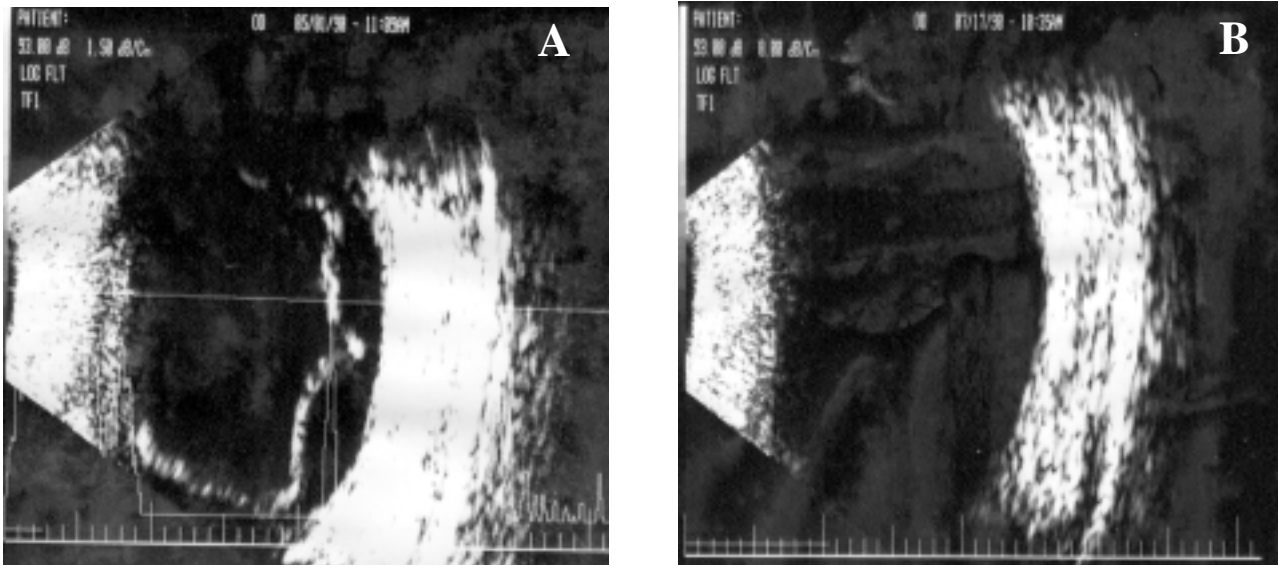


**Fig. 1** Hemorrhagic choroidal detachment (A) and resolution of choroidal detachment after treatment (B) noted by ultrasonography in patient No. 1

and there was no aqueous leakage in the bleb area or cyclodialysis.

Fundus examination and ultrasonography both showed choroidal detachment (Fig. 2A).

After treatment with topical corticosteroid and a cycloplegic agent, the choroidal detachment slowly resolved over one month (Fig. 2B). The visual acuity improved to 20/100 with deeper AC but the IOP persisted at a low level of between 4 and 5 mmHg with thin but no leakage in the bleb area.



**Fig. 2** Choroidal detachment (A) was noted by ultrasonography in patient No. 3. It was completely resolved (B) after one month.

### Case 6

A 78-year-old female with a medical history of diabetic mellitus, hypertension and asthma. She was noted to have hypertensive retinopathy with branch retinal vein occlusion and chronic open-angle glaucoma in her right eye when she first visited our hospital several years ago. The C/D ratio appeared as  $0.7 \times 0.7$  in the right eye and the IOP data showed 22 mmHg but she did not receive regular control. In Jan 2003, she was sent to our OPD due to right eye pain, and her visual acuity had decreased to light perception. Total lens opacity with an IOP of 31 mmHg was observed in the following examination, so cataract surgery combined with trabeculectomy was arranged for the next day.

Intraoperative vitreous loss occurred after cataract extraction and an intraocular lens was not inserted at that time. The next postoperative day the eye showed corneal edema, moderate anterior chamber reaction with exudate formation, an elevated IOP of 34 mmHg and choroidal detachment at the temporal area in the right eye (Fig. 3A). Topical corticosteroid, cycloplegic and anti-glaucoma agents were given and choroidal detachment was resolved after three weeks (Fig. 3B).

Although there was continuous medical control, the IOP persisted at a high level of about 30 mmHg with pale disc appearance and the visual acuity of the

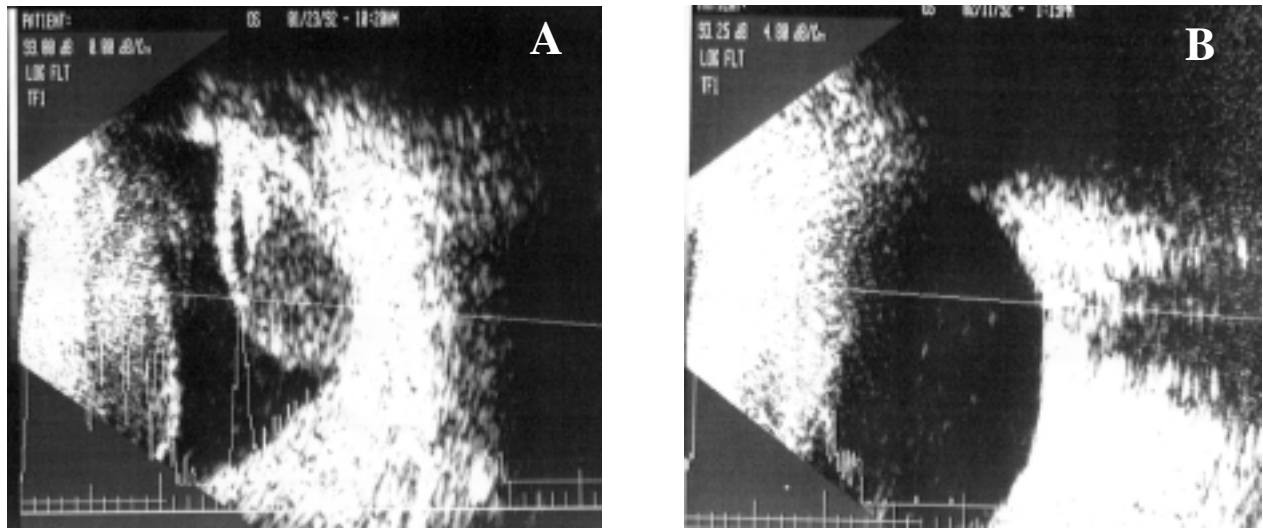
right eye diminished to no light perception.

### DISCUSSION

Choroidal detachment is one of the complications after filtering surgery. A choroidal detachment occurs when transudate fluid crosses the capillary walls of the choroid and collects in the potential space between the uvea and sclera.<sup>(5)</sup> The surgical trauma of trabeculectomy and intraoperative hypotony may stimulate the development of uveal inflammation and an increase in the fluid content of the choroidal stroma, which in turn leads to choroidal detachment and decreased aqueous formation. The aqueous hyposecretion clinically seen may not only result from concurrent iridocyclitis but also from ciliary body detachment.<sup>(7)</sup> Eyes with abnormal sclera that compress the vortex veins and eyes with abnormal vessels due to atherosclerotic or diabetic change may have a higher risk of choroidal detachment.<sup>(4,8)</sup>

In this study, three of our eight cases had a history of systemic hypertension and diabetes mellitus. In case 1, idiopathic scleromalacia and chronic iritis lead to a condition of aqueous hyposecretion and abnormal blood flow from the eye.

The most common causes of hypotony after trabeculectomy are overfiltration and wound or bleb



**Fig. 3** Choroidal detachment in the temporal area (A) occurred in patient No. 6. It was totally resolved (B) after three weeks treatment.

leakage. Other causes of low IOP such as retinal detachment, iridocyclitis and cyclodialysis must also be considered.<sup>(9,10)</sup> Hypotony with a shallow anterior chamber was noted in five of our eight cases. Cases 2, 5 and 7 developed an acute hypotony with choroidal detachment several days after surgery, whereas cases 3 and 4 developed it in the late postoperative period. Possible explanations for late hypotony include use of aqueous suppressants, eye trauma with leakage of aqueous fluid and use of antimetabolites in trabeculectomy,<sup>(9,10)</sup> which were all noted in case 4. Despite no obvious trauma, aqueous leakage or surgical cyclodialysis was noted in case 3; hypotony may have been induced by bleb overfiltration and inflammation.<sup>(11)</sup> Another possible factor for choroidal detachment is full-thickness filtration surgery, which may be performed in older patients. The most significant complication in the chronic hypotonic eye is hypotonic maculopathy but this was not present in our cases.

Not all cases of ciliochoroidal detachment are associated with a low IOP. In cases 1, 6 and 8, normal to high IOP with a shallow anterior chamber was noted several days after surgery. Ciliochoroidal detachment that causes an anterior rotation of the ciliary body-iris diaphragm may lead to angle closure glaucoma in patients with normal or even increased IOP.<sup>(12)</sup> Furthermore, suprachoroidal hemorrhage accompanied by the abrupt onset of pain was noted

with annular peripheral choroidal detachment in case

The risk factors of suprachoroidal hemorrhage including aphakia, excessive myopia and vitreous loss and these were all noted in this patient. Postoperative hypotony and choroidal detachment may worsen the scleral infolding in idiopathic scleromalacia and more easily allow ciliary artery rupture. In cases 1 and 6, IOP elevation when choroidal detachment occurred may have resulted from a severe anterior chamber reaction with hyphema, exudates or protruding vitreous when in an aphakic state.

Besides fundus examination, choroidal detachment could be detected by ultrasonography in all of our cases. A choroidal detachment can be recognized on B-scan as a smooth, thick, dome-shaped membrane on the periphery, with little after movement on kinetic evaluation. Generally, annular peripheral serous choroidal detachments typically do not extend posteriorly to the equator, whereas hemorrhagic choroidal detachments may extend as far as the posterior pole.<sup>(12)</sup> When using A-scan, the location, height, appearance and movement spike of the choroids can help us to differentiate choroidal detachment from retinal detachment or other conditions.<sup>(13)</sup>

In our cases, all eight patients received medical treatment alone and ultimately showed complete resolution of the choroidal detachment. Previous topical

and systemic aqueous suppressant therapy was discontinued and aggressive therapy for ocular inflammation with topical and oral corticosteroids was given. A topical cycloplegic agent was used for a shallow anterior chamber as this treatment tightens the zonules and thereby pulls the lens back onto the plane of the ciliary body, against the force of the vitreous. The counterforce against the vitreous may rotate the iris-ciliary body complex enough to open the trabecular meshwork and reduce the IOP.<sup>(4)</sup> Although choroidal detachment was resolved, six of our cases required topical anti-glaucoma agents for IOP control, and case 6 and case 8 persisted in having a high poorly controlled IOP. The bleb leakage of case 4 became spontaneously sealed as the choroidal detachment resolved but persistent hypotony was noted. The final visual acuity after choroidal detachment resolution improved in most of our cases, except case 6.

## REFERENCES

1. Brubaker RF, Pederson JE. Ciliochoroidal detachment. *Surv Ophthalmol* 1983;27:281-9.
2. Brav SS. Serous choroidal detachment. *Surv Ophthalmol* 1961;6:395-415.
3. Pederson JE. Choroidal detachment. [Discussion] *Ophthalmology* 1981;88:1114-5.
4. Bellows AR, Chylack LT, Hutchinson BT. Choroidal detachment: clinical manifestation, therapy and mechanism of formation. *Ophthalmology* 1981;88:1107-14.
5. Berke SJ, Bellows AR, Shingleton BJ, Richter CU, Hutchinson BT. Chronic and recurrent chroidal detachment after glaucoma filtering surgery. *Ophthalmology* 1987;94:154-62.
6. Chu TG. Suprachoroidal hemorrhage. *Surv Ophthalmol* 1999;43:471-86.
7. Pederson JE. Ocular hypotony. In: Ritch R, Shield MB, Krupin T, eds. *The Glaucomas*. St Louis: CV Mosby, 1989;chap 13.
8. Rachmiel R. Recurrent choroidal detachment following combined trabeculectomy and cataract extraction. *Ophthalmic Surgery and Lasers* 1996;27:795-7.
9. Burney EN, Quigley HA, Robin AL. Hypotony and choroidal detachment as late complications of trabeculectomy. *Am J Ophthalmol* 1987;103:685-8.
10. Catherine M. Birt et al. Late postoperative hypotony and choroidal detachment. *Can J Ophthalmol* 1996;31:125-9.
11. Fourman S. Angle-closure glaucoma complicating ciliochoroidal detachment. *Ophthalmology* 1989;96:646-53.
12. Dugel PU, Heuer DK. Annular peripheral choroidal detachment simulating aqueous misdirection after glaucoma surgery. *Ophthalmology* 1997;104:439-4.
13. Green RL, Byrne SF. Diagnostic ophthalmic ultrasound. In: Ryan SJ, ed. *Retina*. Vol. 1. Basic Science and Inherited Retinal Disease. St Louis: CV Mosby, 1994; chap 17.
14. Chandler PA, Maumenee AE. A major cause of hypotony. *Am J Ophthalmol* 1961;52:609-18.
15. McClure HL. Massive bilateral choroidal detachment occurring in an aphakic patient six years and nine months postoperatively. *Am J Ophthalmol* 1967;63:295-7.
16. Lamping KA, Bellows AR, Hutchinson BT, Afran SI. Long-term evaluation of initial filtration surgery. *Ophthalmology* 1986;93:91-101.
17. Mills KB. Trabeculectomy: a long-term follow-up of 444 cases. *Br J Ophthalmol*. 1981;65:790-4.
18. Capper SA, Leopold IH. Mechanism of serous choroidal detachment. A review and experimental study. *Arch Ophthalmol* 1956;55:101-13.
19. Gass JDM. Uveal effusion syndrome. A new hypothesis concerning pathogenesis and technique of surgical treatment. *Trans Am Ophthalmol Soc* 1983;81:246-60.
20. Gass JDM, Jallow S. Idiopathic serous detachment of the choroids, ciliary body, and retina (uveal effusion syndrome). *Ophthalmology* 1982;89:1018-32.
21. Dodds EM, Lander CY, Barnhorst DA. Posterior scleritis with annular ciliochoroidal detachment. *Am J Ophthalmol* 1995;120:677-9.

## 青光眼引流術後之脈絡膜剝離

古婉珍 林穎新 莊蘭馨 楊克仁

**背景：** 本文之目的在於探討青光眼引流術後，引起脈絡膜剝離之8位患者，研究其臨床表現，診斷，及治療。

**方法：** 本文蒐集了基隆長庚醫院在2002年至2004年間，在接受青光眼引流術或合併青光眼及白內障手術後引起脈絡膜剝離的8位病患進行研究。對於病患的性別、年齡、術前診斷、術前用藥、手術方式加以分析，並且觀察術後脈絡膜剝離發生的時間，視力變化，診斷方法及治療結果。8位病患中有一位是慢性虹彩炎引起之續發性青光眼，5位是原發性隅角開放型青光眼，兩位是慢性隅角閉鎖型青光眼。8位病患中有6位在手術後兩週內發現急性脈絡膜剝離，有兩位則是在手術過後數年發現。8位病患中有5位接受青光眼手術合併白內障手術，有兩位在術中使用抗纖維化藥劑。所有病患臨床上皆表現視力模糊合併眼痛，及前房狹窄的現象，有6位病患表現出低眼壓。治療上包括局部散瞳劑及口服或局部類固醇治療。

**結果：** 經過數週的治療後，所有病患臨床上脈絡膜剝離的情況皆獲得緩解，但有兩位病患仍持續有不易控制的高眼壓。除了眼底檢查以外，超音波檢查也被用作為脈絡膜剝離的診斷依據。

**結論：** 脈絡膜剝離是青光眼術後可能引起的併發症之一，超音波檢查可作為診斷脈絡膜剝離的適當工具，經藥物治療後可使脈絡膜剝離獲得緩解。  
(長庚醫誌 2005;28:151-8)

**關鍵字：** 脈絡膜剝離，小樑切除術，超音波，類固醇治療。

---

長庚紀念醫院 基隆院區 眼科

受文日期：民國93年11月2日；接受刊載：民國94年1月13日。

索取抽印本處：古婉珍醫師，長庚紀念醫院 眼科。基隆市204麥金路222號。Tel.: (02)24313131轉2553; Fax: (02)24311190; E-mail: susanna@cgmh.org.tw