

Visual Results and Complications after Trans Pars Plana Vitrectomy and Lensectomy for Lens Dislocation

Hsiu-Mei Huang, MD; Min-Lun Kao, MD; His-Kung Kuo, MD; Shih-Hao Tsai, MD; Yung-Jen Chen, MD; Chi-Chang Liu, MD

Background: The aim of this study is to determine the relationship between the cause of lens dislocation and visual outcomes with complications in patients undergoing trans pars plana vitrectomy (TPPV) and trans pars plana lensectomy (TPPL) for lens dislocation.

Methods: This retrospective study was carried out from July 1995 through November 2003. After excluding patients with previous retinal detachment or combing lens dislocation and post-TPPV/TPPL follow-up intervals of less than 6 months, 36 eyes from 36 patients who had undergone vitrectomy and lensectomy for lens subluxation or dislocation due to trauma or intraocular surgery were examined. Their presenting features and complications were recorded. The relationship between the cause of lens dislocation and visual outcome with complications was tested using Fisher's exact test.

Results: The cause of lens dislocation included blunt and penetrating eye trauma, and intraocular surgery. Final best-corrected visual acuity was 20/40 or better in 45% of eyes in the traumatic arm and in 31% of eyes in the iatrogenic arm. Visual acuity improved after TPPV/TPPL in 90% of the eyes in the traumatic arm and in 81% of the eyes in the iatrogenic arm. Of all of the eyes, 39% had significant complications affecting postoperative visual outcomes, including retinal detachment, cystoid macular edema, vitreous hemorrhage and glaucoma.

Conclusions: There were no significant differences in visual outcomes and complications between the traumatic and iatrogenic arms of the study. Therefore, the cause of lens dislocation was not a predictor of visual outcomes. Nonetheless, posterior segment complications including retinal detachment and glaucoma were major causes of poor postoperative visual outcomes.

(Chang Gung Med J 2004;27:429-35)

Key words: lens dislocation, trans pars plana vitrectomy, trans pars plana lensectomy, retinal detachment.

Posterior dislocation or subluxation of a lens fragment or an intraocular lens is a well-known complication following trauma and cataract extraction

surgery. Retained lens materials in the vitreous cavity can lead to poor visual acuity and related inflammation, corneal edema, and glaucoma. Pars plana

From the Department of Ophthalmology, Chang Gung Memorial Hospital, Kaohsiung.

Received: Dec. 22, 2003; Accepted: Mar. 22, 2004

Address for reprints: Dr. Shih-Hao Tsai, Department of Ophthalmology, Chang Gung Memorial Hospital, 123, Dabi Road, Niasung Shiang, Kaohsiung, Taiwan 833, R.O.C. Tel.: 886-7-7317123 ext. 2801; Fax: 886-7-7317123 ext. 2830; E-mail: ciba@ms2.hinet.net

vitrectomy and lensectomy are frequently necessary to remove the dislocated lens materials. Generally, the visual prognosis for patients undergoing vitrectomy for a retained lens fragment is good.⁽¹⁾ Nonetheless, the leading causes of poor visual outcome include retinal detachment, cystoid macular edema, and corneal edema.⁽¹⁻¹³⁾ The aim of this study was to determine the relationship between the causes of lens dislocation and visual outcomes with complications among patients undergoing trans pars plana vitrectomy (TPPV) and trans pars plana lensectomy (TPPL) for lens dislocation. Furthermore, we evaluated the differences in prognosis between the different causes of lens dislocation.

METHODS

This study was a retrospective, comparative, interventional, and consecutive case series. The medical records of all patients who underwent TPPV/TPPL for lens dislocation or subluxation after intraocular surgery and trauma at Kaohsiung Chang Gung Memorial Hospital Eye Institute between July 1, 1995 and November 30, 2003 were reviewed. Patients with previous retinal detachment, lens dislocation/subluxation and retinal detachment, and those with less than 6 months post-TPPV/TPPL follow-up were excluded.

The preoperative data were obtained from each patient's records including, age, sex, type of injury, duration of interval from injury to presentation, best-corrected visual acuity (BCVA), and evidence of posterior segment trauma. Postoperative data included duration of a follow-up interval, BCVA, posterior segment abnormalities, and any subsequent postoperative procedures. Statistical analysis was performed using Fisher's exact to compare the different causes of lens dislocation/subluxation with postoperative visual outcomes.

RESULTS

The study included 36 eyes of 36 patients, with a mean patient age of 56 years (range, 19-79 years). There were 30 men and 6 women (Table 1). The causes of lens dislocation/subluxation included trauma in 20 patients, and intraocular surgery in 16 patients. The mean follow-up interval after TPPV/TPPL was 19 months (range, 6-67 months).

The median time from lens dislocation to TPPV/TPPL was 8.5 days (range, 1-1825 days). The pre-TPPV/TPPL best-corrected visual acuity was 20/200 or better in 10% (2 patients) of eyes in the trauma group, and in 18.75% (3 patients) of eyes in the iatrogenic group.

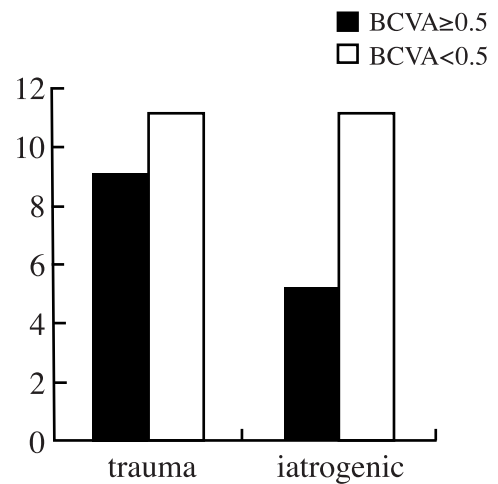


Fig. 1 After TPPV/TPPL for lens dislocation, 14 patients (39%) had best-corrected visual acuity of 20/40 or better, along with 9 patients (45%) in the trauma group (20 patients), and 5 patients (31%) in the iatrogenic group (16 patients). There were no associations between final BCVA of 20/40 or better ($p=0.164$) and the causes of lens dislocation.

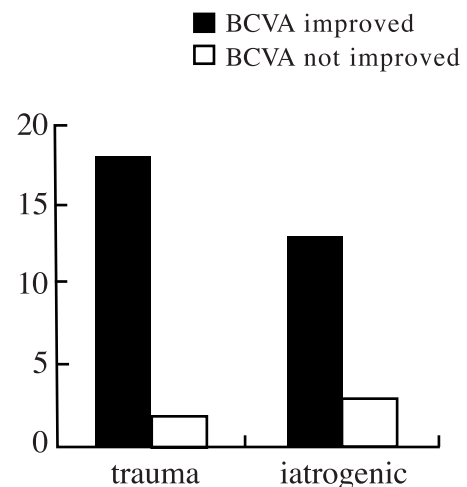


Fig. 2 Visual acuity improved after TPPV/TPPL in 90% of eyes (18 patients) in the trauma group (20 patients) and 81% (13 patients) in the iatrogenic group (16 patients). There were no associations between postoperative BCVA improvement ($p=0.269$) and the causes of lens dislocation.

Table 1. Patients' Data

Patient	Age (years)	Gender	Lesion eye	Cause	pre-op anatomy	pre-op BCVA	Final BCVA
1	72	M	OD	post cata	lens dislocation	20/100	20/600
2	76	M	OS	post cata	lens dislocation in vitreous	cf>1m	20/40
3	62	M	OD	post cata	lens dislocation in vitreous +2nd uveitis + G	cf/40 cm	20/50
4	58	M	OD	post cata	"lens in vitreous, VH, Uveitis"	cf/5 cm	20/200
5	36	M	OS	post cata	VH+lens dislocation in vitreous	cf/20 cm	20/1000
6	68	F	OS	post cata	lens in vitreous	cf/15 cm	20/100
7	55	F	OS	post cata	lens dislocation in vitreous	cf/70 cm	20/40
8	63	F	OS	post cata	lens dislocation in vitreous	20/2000	20/100
9	69	F	OS	post cata	lens in vitreous	cf/15 cm	20/60
10	68	M	OD	post cata	lens dislocation to vitreous cavity	cf/10 cm	20/40
11	68	M	OD	postTPPV	lens in vitreous	cf/10 cm	20/40
12	69	M	OD	post cata	lens in vitreous	20/100	20/200
13	72	M	OD	post cata	lens subluxation	20/100	20/600
14	66	F	OS	post cata	"lens in vitreous, VH"	cf/10 cm	20/50
15	71	M	OD	post cata	"lens in vitreous, exudation"	hm/15 cm	20/30
16	63	M	OD	post cata	"lens in vitreous, G"	cf/5 cm	0.04
17	34	M	OS	trauma	"DM fold, Hyphema, VH, lens in vitreous"	cf/5 cm	20/30
18	19	M	OD	trauma	"VH, lens in Vitreous, sub R& macula H"	hm/30 cm	cf/30 cm
19	47	M	OS	trauma	lens dislocation in vitreous	cf/10 cm	20/600
20	37	M	OD	trauma	lens dislocation in vitreous	20/400	20/100
21	68	M	OS	trauma	"lens dislocation in vitreous, VH+G"	cf/20 cm	20/40
22	42	M	OS	trauma	"DM fold, iridodialysis, lens in AC, VH, Pre-Retinal hemorrhage, G"	20/400	20/20
23	39	M	OD	trauma	"lens in Vitreous, VH, macula hole"	hm/10 cm	20/500
24	25	M	OS	trauma	"iridodialysis, hyphema, lens in AC & vitreous, dot hemorrhage"	cf/20 cm	20/200
25	40	M	OS	trauma	"hyphema, G, lens in vitreous"	hm/20 cm	20/40
26	66	M	OS	trauma	"hyphema, VH, G, lens in Vitreous, pre-R H"	hm/30 cm	20/600
27	68	M	OS	trauma	"lens in vitreous, G, hyphema,"	hm/50 cm	20/2000
28	65	M	OD	trauma	Lens dislocation in vitreous+G+VH	cf/30 cm	20/500
29	61	M	OD	trauma	lens dislocation in vitreous+G+iridodialysis+ macula hole	hm/50-60 cm	20/2000
30	45	F	OS	trauma	"lens in vitreous, G, hyphema"	cf/25 cm	20/30
31	45	M	OD	trauma	"lens subluxation, iridodialysis"	20/60	20/40
32	63	M	OD	trauma	lens dislocation in vitreous	cf/10 cm	20/60
33	28	M	OS	trauma	lens dislocation in vitreous	hm/1M	20/20
34	51	M	OS	trauma	"lens in vitreous, G"	cf/10 cm	20/40
35	55	M	OS	trauma	"lens in vitreous & AC, hyphema, G"	20/40	20/500
36	66	M	OS	trauma	"lens in AC, VH"	20/1000	20/25

Abbreviations: OD: oculus dexter; OS: oculus sinister; AC: anterior chamber; BCVA: best-corrected visual acuity, CD: choroidal detachment; TPPV: trans pars plana vitrectomy; TPPL: trans pars plana lensectomy; VH: vitreous hemorrhage.

At final follow-up, a total of 14 patients (39%) had a BCVA of 20/40 or better, including 9 patients (45%) in the trauma group (20 patients) and 5 patients (31.25%) in the iatrogenic group (16 patients). Visual acuity improved after TPPV/TPPL

for 18 eyes (90%) in the trauma group and 13 eyes (81.25%) in the iatrogenic group.

Of the 36 eyes, 39% (14 eyes) had significant complications affecting postoperative visual outcome, including retinal detachment in 2 (5.6%, one

Table 1. (cont)

Op method	F/U period (mo)	post-op anatomy	subsequent surgery
TPPV;TPPL	24		
TPPV,TPPL	12		
TPPV,TPPL	12		
"TPPV,TPPL"	6		
TPPV,TPPL	10		
TPPV, TPPL	83	G	
TPPV,TPPL	14		
TPPV,TPPL	40		
TPPV,TPPL	66		
TPPV,TPPL	34		
"TPPV,TPPL"	44		
"TPPV, TPPL"	8	"CME, choroidal fold"	
"TPPV,TPPL"	24	"inferior RD(2m) "	"SB,TPPV"->CME,G
"TPPV, TPPL"	12	endophthalmitis(1y)	
"TPPV, TPPL"	25	"dot hemorrhage, G"	
"TPPV, TPPL"	6		
TPPV,TPPL	23	G	
TPPV,TPPL	6	"G, subretina hemorrhage in macula"	Trabeculectomy (30d)
TPPV,TPPL	6		
TPPV,TPPL	6		
TPPV,TPPL	21		
TPPV,TPPL	13	"VH, G"	
"TPPV,TPPL"	9	G	Trabeculectomy (6d)
"TPPV,TPPL"	6	Sub-retinal fibrosis	
"TPPV,TPPL"	13		
"TPPV,TPPL"	10	"G, choroidal rupture"	Trabeculectomy (31d)
"TPPV,TPPL"	14	RD(1y)	"SE, TPPV"
TPPV,TPPL	6		
TPPV,TPPL	6		
TPPV, TPPL	67	G	
"TPPV, TPPL"	7		
TPPV,TPPL	13		
TPPV,TPPL	6		
"TPPV,TPPL"	7		
TPPV,TPPL	6	G	
"TPPV, TPPL"	12		

ment; CME: cystoid macular edema; DM: Descemet's membrane; G: glaucoma; RD: retinal detachment; SB: scleral buckling; TPPV: trans

in the iatrogenic group), cystoid macular edema in 2 (5.6%, both in the iatrogenic group), glaucoma in 9 (24%, 2 in the iatrogenic group), subretinal fibrosis in 1 (2.78%, in trauma group), and submacular hemorrhage in 1 (2.78%, in trauma group).

There were no associations between the final BCVA of 20/40 or better ($p=0.164$, Fig. 1), BCVA improvement ($p=0.269$, Fig. 2), and complications affecting visual outcome ($p=0.105$, Fig. 3) with the causes of lens dislocation.

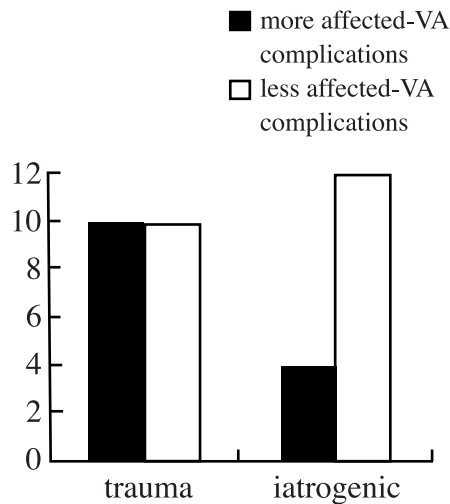


Fig. 3 Of the 36 eyes, 39% had significant complications affecting postoperative visual outcome. After TPPV/TPPL, affected-VA complications were noted in 50% of eyes (10 patients) in the trauma group (20 patients) and in 25% of eyes (4 patients) in the iatrogenic group (16 patients). There were no associations between complications affecting visual outcome ($p=0.105$) and the causes of lens dislocation.

DISCUSSION

The reported incidence of posterior dislocation of lens fragments after cataract surgery ranges from 0.3% to 1.1%.^(14,15) The risk factors associated with dropped nuclei include posterior polar cataracts, dense cataracts, radial tears in the capsulorrhexis, topical anesthesia, and history of vitrectomy.⁽¹⁶⁾ Additionally, pseudoexfoliation, diabetes mellitus, Marfan syndrome, trauma, hypermature cataracts, and cataracts associated with persistent hyperplastic primary vitreous are predisposing factors for posterior capsular tears, which can lead to the loss of lens fragments.⁽¹⁷⁾

We evaluated the relationships between different causes of lens dislocation, including intraocular surgery and trauma. Of the 36 eyes (36 patients), there were 20 eyes in the trauma group, and 16 eyes in the iatrogenic group. Regardless of the cause of lens dislocation/subluxation, the complications of the retained lens material associated with poor visual acuity included intraocular inflammation, corneal edema, elevated intraocular pressure, retinal detach-

ment, and vitreous hemorrhage.⁽¹⁸⁾

TPPV/TPPL was the best method to manage the dislocated lens and resulting pathology, especially nuclear remnants, marked intraocular inflammation, uncontrolled glaucoma, retinal detachment, or evidence consistent with endophthalmitis. The goal of the vitreoretinal surgeon is to remove the retained lens material while avoiding vitreous traction and retinal injury.⁽¹⁾ In our study, lens dislocation was combined with anatomic abnormalities and poor pre-operative visual acuity, including vitreous hemorrhage in 11 eyes (8 in the trauma group), elevated intraocular pressure in 12 eyes (10 in the trauma group), traumatic hyphema in 7 eyes (all in the trauma group) and ocular inflammation in 2 eyes (all in the iatrogenic group).

The visual prognosis for patients undergoing vitrectomy for lens dislocation due to cataract either extraction or ocular blunt trauma is good.⁽¹⁹⁻²²⁾ The leading causes of poor visual outcome include retinal detachment, cystoid macular edema, and corneal edema.⁽¹⁻¹³⁾ Moore et al. reported that the rate of retinal detachment after vitrectomy was 5.5%. Retinal reattachment was usually achieved, but the visual outcomes were often poor and were associated with other comorbidities such as corneal edema and cystoid macular edema.⁽²³⁾ Smiddy and Flynn proposed that retinal detachment after vitrectomy for retained lens material was attributable to one of two categories of causes that may not be clinically distinguishable.⁽³⁾ In one category, the pathogenic break may occur during vitrectomy due to manipulations through and at the vitreous base; retinal detachment would be expected to occur within about 1 week of surgery. Many occurrences of retinal detachment in this category might be preventable by treating the retinal break intraoperatively with compulsory ophthalmoscopic evaluation of the retinal periphery at the conclusion of surgery. In the second category, the retinal break may occur after vitrectomy, and it is possibly attributable to inflammation-driven vitreous base cicatrization stimulated by a combination of cataract surgery, retained lens material, vitrectomy surgery, or IOL manipulations. These breaks would be more difficult to prevent; the maximal removal of vitreous, induction of posterior vitreous detachment (PVD), and maximal control of postoperative inflammation may represent the best strategies for avoiding this type of complication.⁽²⁴⁾

In our study, 39% (14 eyes) had significant complications affecting postoperative visual outcome, including retinal detachment in 2 (5.6%), cystoid macular edema in 2 (5.6%), glaucoma in 9 (24%), subretinal fibrosis in 1 (2.78%), and submacular hemorrhage in 1 (2.78%).

For the two patients with retinal detachment, both underwent secondary TPPV and encircling scleral buckling surgery, but their final visual acuity was still poor (<20/600) due to cystoid macular edema with glaucoma after vitrectomy. There were no associations between final BCVA of 20/40 or better ($p=0.164$), and improved BCVA ($p=0.269$) with the causes of lens dislocation. There was no statistically significant relationship between the complications affecting visual outcome with the causes of lens dislocation ($p=0.105$), however, that could have resulted from the insufficient numbers of patients.

The limitations of our study include its retrospective nature and its small sample size. Nonetheless, posterior segment complications including retinal detachment and cystoid macular edema still caused the majority of poor postoperative visual outcomes.

REFERENCES

1. Kim IK, Miller JW. Management of dislocated lens material. *Semin Ophthalmol* 2002;17:162-6.
2. Hutton WL, Snyder WB, Vaiser A. Management of surgically dislocated intravitreal lens fragments by pars plana vitrectomy. *Ophthalmology* 1978;85:176-89.
3. Smiddy WE, Flynn HW Jr. Managing retained lens fragments and dislocated posterior chamber IOLs after cataract surgery. *Focal Points* 1996;14:9.
4. Hansson LJ, Larsson J. Vitrectomy for retained lens fragments in the vitreous after phacoemulsification. *J Cataract Refract Surg* 2002;28:1007-11.
5. Bessant DA, Sullivan PM, Aylward GW. The management of dislocated lens material after phacoemulsification. *Eye* 1998;12:641-5.
6. Kapusta MA, Chen JC, Lam WC. Outcomes of dropped nucleus during phacoemulsification. *Ophthalmology* 1996;103:1184-7.
7. Wilkinson CP, Green WR. Vitrectomy for retained lens material after cataract extraction. The relationship between histopathologic findings and the time of vitreous surgery. *Ophthalmology* 2001;108:1633-7.
8. Irvine WD, Flynn HW Jr, Murray TG, Rubsam PE. Retained lens fragments after phacoemulsification manifesting as marked intraocular inflammation with hypopyon. *Am J Ophthalmol* 1992;114:610-4.
9. Oruc S, Kaplan HJ. Outcome of vitrectomy for retained lens fragments after phacoemulsification. *Ocular Immunol Inflamm* 2001;9:41-7.
10. Gilliland GD, Hutton WL, Fuller DG. Retained intravitreal lens fragments after cataract surgery. *Ophthalmology* 1992;99:1263-9.
11. Stilma JS, van der Sluijs FA, van Meurs JC, Mertens DAE. Occurrence of retained lens fragments after phacoemulsification in the Netherlands. *J Cataract Refract Surg* 1997;23:1177-82.
12. Fastenberg DM, Schwartz PL, Shakin JL, Golub BM. Management of dislocated nuclear fragments after phacoemulsification. *Am J Ophthalmol* 1991;112:535-9.
13. Ross WH. Management of dislocated lens fragments after phacoemulsification surgery. *Can J Ophthalmol* 1996;31:234-40.
14. Scott IU, Flynn HW. Retained lens fragments after cataract surgery. *Ophthalmol Clin North Am* 2001;14:675-9.
15. Monshizadeh R, Samily N, Haimovici R. Management of retained intravitreal lens fragments after cataract surgery. *Surv Ophthalmol* 1999;43:397-404.
16. Aasuri MK, Kompella VB, Majji AB. Risk factors for and management of dropped nucleus during phacoemulsification. *J Cataract Refract Surg* 2001;27:1428-32.
17. Vajpayee RB, Sherma N, Dada T, Gupta V, Kumar A, Dada VK. Management of posterior capsule tears. *Surv Ophthalmol* 2001;45:473-88.
18. Blodi BA, Flynn HW, Jr., Blodi CF, Folk JC, Daily MJ. Retained nuclei after cataract surgery. *Ophthalmology* 1992;99:41-4.
19. Borne MJ, Tasman W, Regillo C, Malecha M, Sarin L. Outcomes of vitrectomy for retained for retained lens fragments. *Ophthalmology* 1996;103:971-6.
20. Margherio RR, Margherio AR, Pendergast SD. Vitrectomy for retained lens fragments after phacoemulsification. *Ophthalmology* 1997;104:1426-32.
21. Vilar NF, Flynn HW, Jr., Smiddy WE, Murray TG, Davis JL, Rubsam PE. Removal of retained lens fragments after phacoemulsification reverses secondary glaucoma and restores visual acuity. *Ophthalmology* 1997;104:787-91.
22. Greven CM, Collins AS, Slusher MM, Weaver RG. Visual results, prognostic indicators, and posterior segment findings following surgery cataract/lens subluxation-dislocation secondary to ocular contusion injury. *Retina* 2002;22:575-80.
23. Moore JK, Scott IU, Flynn HW Jr, Smiddy WE, Murray TG, Kim JE, Vilar NF, Pereira MB, Jorge R. Retinal detachment in eyes undergoing pars plana vitrectomy for removal of retained lens fragments. *Ophthalmology* 2003;110:709-14.
24. Smiddy WE, Guerro JL, Pinto R, Feuer W. Retinal detachment rate after vitrectomy for retained lens material after phacoemulsification. *Am J Ophthalmol* 2003;135:183-7.

因水晶體脫位所作之玻璃體併水晶體切除術術後之視力及併發症之探討

黃修眉 郭明倫 郭錫恭 蔡世豪 陳勇仁 劉其璋

背景： 探討水晶體脫位之原因與玻璃體併水晶體切除術，術後視力結果的相關性。

方法： 從1995至2003年當中，排除水晶體脫位合併視網膜剝離及追蹤時間少於6個月者，共有36個病人36個眼睛執行因水晶體脫位而作的玻璃體切除術。患者之臨床表現如文中所述。水晶體脫位之原因與術後之視力結果的相關性的探討是利用費氏統計法。

結果： 造成水晶體脫位的原因包括創傷，及眼球內手術。在創傷組及眼球內術後組的玻璃體切除術術後之視力超過20/40者分別佔45%及31%，視力改善者分別佔90%及81%。兩組對於術後視力的好壞並無統計上的意義。39%的病例有明顯影響術後視力之併發症。術後明顯影響視力的因子包括視網膜剝離，黃斑部水腫，及青光眼。

結論： 水晶體脫位的原因與其術後之視力並無明顯相關性，因此水晶體脫位的原因並不能成為預估術後視力的重要因子。然而術後之後極部併發症因為會造成術後較差之視力，故可作為評估術後視力之考量。

(長庚醫誌 2004;27:429-35)

關鍵字： 水晶體脫位，玻璃體切除術，經平板部水晶體切除術，視網膜剝離。

長庚紀念醫院 高雄院區 眼科系

受文日期：民國92年12月22日；接受刊載：民國93年3月22日。

索取抽印本處：蔡世豪醫師，長庚紀念醫院 眼科系。高雄縣833烏松鄉大埤路123號。Tel.: (07)7317123轉2801; Fax: (07)7317123轉2830; E-mail: ciba@ms2.hinet.net