

## Idiopathic Pulmonary Fibrosis in a Child

Kuei-Wen Chang, MD; Chang-Teng Wu, MD; Shiu-Feng Huang<sup>1</sup>, MD;  
Tang-Her Jiang, MD; Kin-Sun Wong, MD

Idiopathic pulmonary fibrosis (IPF) is a rare disease of unknown etiology and is usually associated with a poor prognosis. Up to the present, less than 50 cases of IPF in children have been reported in the English literature, and no case has ever been reported from Taiwan. Herein we report on a 2-year-old boy with IPF presenting with a rapid onset of dyspnea followed by respiratory failure. The diagnosis of IPF was verified with an open lung biopsy. Despite intravenous methylprednisolone pulse therapy and empiric nitric oxide treatment, he expired on the 35th day after admission due to profound hypoxemia. A diagnosis of IPF should be included in the differential diagnosis for patients presenting with unexplained shortness of breath and pulmonary interstitial infiltrations. (*Chang Gung Med J* 2003;26:60-4)

**Key words:** childhood idiopathic pulmonary fibrosis, corticosteroid pulse therapy.

Idiopathic pulmonary fibrosis (IPF) is a highly lethal disorder associated with an extremely poor prognosis in most patients.<sup>(1)</sup> The median duration of survival is approximately 4 years.<sup>(2)</sup> It is a chronic inflammatory interstitial lung disorder characterized by initial accumulations of inflammatory and immunoregulatory cells in the pulmonary interstitium and later in the alveolar spaces.<sup>(3)</sup> In children, pulmonary fibrosis is a heterogeneous group of disorders of both known and unknown causes that show common histological features.<sup>(3)</sup> The known causes include infectious disorders in immunocompetent or immunocompromised patients, reactions to occupational or environmental exposures, drugs, collagen-vascular disorders, and gastroesophageal reflux with chronic aspirations.<sup>(4)</sup> Up to the present, fewer than 50 cases of IPF in children have been reported in the English literature, and no case has been reported from Taiwan.<sup>(1,5)</sup> Herein we describe a 2-year-old boy who presented with a rapidly deteriorating course and showed no therapeutic response to pulse

methylprednisolone therapy.

### CASE REPORT

A 2-year-old boy had a 1-week history of coughing and rhinorrhea with dyspneic respiration for 3 days. He had had Kawasaki disease at 1 year of age and had received intravenous immunoglobulin therapy without coronary artery dilatation. Vital signs at admission showed a heart rate of 132 beats/min, a body temperature of 36.8°C, a respiratory rate of 38/min, and a blood pressure of 104/84 mmHg. Physical examination revealed diffuse bilateral expiratory wheezing and inspiratory crackles. The jugular veins were not engorged, and there was no hepatomegaly or lower leg edema.

Laboratory investigations revealed the following results: hemoglobin 2.08 mmol/L; white blood cell counts  $7.5 \times 10^9$  cells/L (80% segmented neutrophils, 14% lymphocytes, 2% eosinophils, 4% monocytes); urea 1.79 mmol/L; creatinine 35  $\mu$ mol/L;

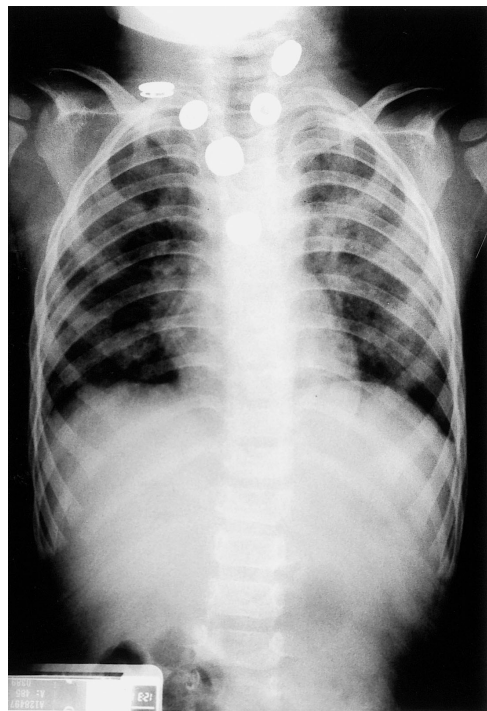
From the Department of Pediatrics, <sup>1</sup>Department of Pathology, Chang Gung Children's Hospital, Taoyuan.

Received: Feb. 25, 2002; Accepted: May 13, 2002

Address for reprints: Dr. Kin-Sun Wong, Department of Pediatrics, Chang Gung Children's Hospital, 5, Fu-Shing Street, Kweishan, Taoyuan 333, Taiwan, R.O.C. Tel.: 886-3-3281200 ext. 8218; Fax: 886-3-3288957

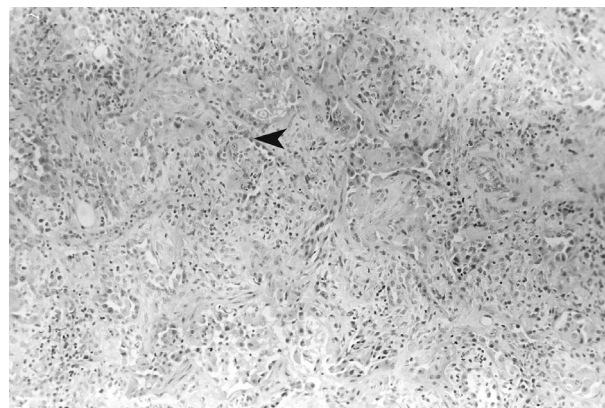
immunoglobulin G (IgG) 7 g/L; IgA 758 mg/L; and IgM 3090 mg/L. Serum  $\alpha$ -1-antitrypsin was 253 (normal, 115.2-166.4) mg/dL. Frontal chest radiography revealed diffuse bilateral interstitial infiltrations (Fig. 1). A lymphocyte subset analysis showed CD3 38%, CD4 24%, CD8 12%, and CD19 55%. Serological tests for acute infections of Epstein-Barr virus, cytomegalovirus, and adenovirus were invariably negative. Cardiac echography revealed a normal anatomy and contractility (with an ejection fraction of 72%). A history of toxin exposure was denied.

The patient was initially admitted to the ward and at first received 4 mg/kg dose of hydrocortisone every 6 hours as treatment for the initial diagnosis of an acute asthmatic attack. However, due to persistent respiratory distress and progressive hypoxemia, he was transferred to the intensive care unit and was subsequently intubated. Arterial blood gas showed pH 7.513, PaCO<sub>2</sub> 30.8, PaO<sub>2</sub> 46.3, AaDO<sub>2</sub> 304.1, and 90% saturation under use of 55% FiO<sub>2</sub>. Flexible bronchoscopy and bronchoalveolar lavage (BAL) were performed. A normal anatomy was found on



**Fig. 1** Chest X-ray revealing bilateral diffuse infiltrations with an interstitial pattern.

bronchoscopy, and the BAL was negative when stained for bacteria. Special staining of the BAL fluid for *Pneumocystis carinii*, fungi, and acid-fast bacilli and iron staining were unrewarding. He received 1 g/kg/day intravenous immunoglobulin from the 15<sup>th</sup> day for 2 days for immunomodulation. An open lung biopsy was performed on the 17<sup>th</sup> day. The histopathology study showed diffuse dense interstitial fibrosis with heavy lymphoplasma cell infiltration and alveolar cell hyperplasia (Fig. 2). Epithelial hyperplasia of the terminal bronchioles was also found with no hyaline membrane formation. There were no viral inclusion bodies. Methylprednisolone at 2 mg/kg/day was given from the 20<sup>th</sup> day and at 10 mg/kg/day for 3 days from the 29<sup>th</sup> day; empiric nitric oxide (NO) (20 ppm) was given for 8 days; and high frequency ventilator support was supplied from the 32<sup>nd</sup> day (Herz 8 times/s, mean airway pressure 29 mmH<sub>2</sub>O, delta pressure 27 mmH<sub>2</sub>O). The hypoxemia persisted, and the patient expired on the 35<sup>th</sup> day due to respiratory failure and profound hypoxemia.



**Fig. 2** Microscopy sections of lung tissue derived from an open lung biopsy. There was diffuse and dense interstitial fibrosis with heavy lymphoplasma cell infiltration and alveolar cell hyperplasia (arrowhead). Epithelial hyperplasia of the terminal bronchioles can be noted. There was neither hyaline membrane formation nor viral inclusion bodies. (H&E stain, original magnification  $\times 200$ )

## DISCUSSION

Although IPF is rare during childhood, its prevalence in the general pediatric population is difficult to establish. According to a recent report on

the epidemiology of interstitial lung disease in adults, interstitial pulmonary fibrosis may be more common than indicated by previous estimates based on selected populations.<sup>(6)</sup> The same may apply to the pediatric population, in which certain forms of interstitial lung disease associated with fibrotic processes may go unrecognized.<sup>(5)</sup>

The cause of IPF remains unknown. A general theory is that a triggering agent or event induces an inflammatory reaction in the lung that perpetuates and causes progressive parenchymal fibrosis.<sup>(3,7)</sup> The presence of immune complexes in the alveoli favors an active participation of T- and B-lymphocytes against endogenous or exogenous antigens.<sup>(8)</sup> It has been suggested that some of the factors leading to lung injuries include oxidants, overexpression of tumor necrosis factor- $\alpha$  (TNF $\alpha$ ), collagenases, and eosinophil cationic protein.<sup>(7-9)</sup> Repair mechanisms following injuries that lead to fibrosis include secretion of platelet-derived growth factor, fibronectin, somatomedin-1 or insulin growth factor, endothelin-1, and thrombin.<sup>(7-9)</sup> In addition to these profibrotic agents, it was recently suggested that a lack of natural inhibitors of collagen synthesis such as prostaglandin E2<sup>(10)</sup> or interferon- $\gamma$ , could predispose one to the occurrence of IPF.<sup>(11)</sup>

Clinical manifestations of IPF are nonspecific. Cough, dyspnea, and inspiratory rales may be found on physical examination. Evidence of restrictive lung disease with reduced diffusion capacity for carbon monoxide and abnormal gas exchange may be demonstrated. Chest imaging may show the appearance of diffuse interstitial infiltrates. This was true in our case. A diagnosis of IPF should be included in the list of differential diagnosis for those patients presenting with unexplained shortness of breath and interstitial infiltration. Open lung biopsy should be considered as soon as IPF is suspected. The histopathological features of an open-lung biopsy specimen have been the strongest predictor of clinical outcomes among patients with interstitial lung disease, but the correlation between histological features and prognosis or response to therapy is unclear.<sup>(12)</sup> A lung biopsy is recommended for IPF when the clinical and radiographic features are atypical, malignancy or unusual infection is suspected, or the response to steroids is unsatisfactory.<sup>(13)</sup>

Effective therapeutic regimens for IPF remain to be determined. The major aims of the various thera-

peutic strategies are to suppress the inflammation in order to reverse the deleterious processes so as to restore normal pulmonary epithelium and oxygenation. Several medications have been proposed which include glucocorticosteroids as well as chloroquine, cyclophosphamide, azathioprine, or colchicine.<sup>(4,12)</sup> High-dose pulse corticosteroid therapy may be more effective than continuous prednisolone at lower doses because of its stronger immunosuppressive effects and lower long-term toxicity.<sup>(5)</sup> However, the adverse effects of pulse steroid therapy include sepsis, hypertension, hyperglycemia, and adrenal insufficiency, and these should be closely monitored. In this case, methylprednisolone pulse therapy was ineffective and was further complicated by sepsis. The optimal dosage and duration of treatment of steroids require further investigation. Cytotoxic therapy (cyclophosphamide and azathioprine) had previously been used primarily in patients with IPF who did not respond to corticosteroids and in those at high risk of steroid complications.<sup>(12)</sup> However, the addition of either cyclophosphamide or azathioprine at a modest dose to corticosteroids may offer a benefit beyond what is achieved by steroids alone.<sup>(5)</sup>

Several new therapies including the administration of cytokine inhibitors, cytokine receptor antagonists, or newer anti-inflammatory and antifibrotic agents<sup>(8)</sup> have been proposed. Anticytokine therapies using interferon- $\gamma$  1b,<sup>(14)</sup> modulators for TNF- $\alpha$ ,<sup>(8)</sup> or transforming growth factor- $\beta$ <sup>(9)</sup> are promising. Another possible approach based on the vascular and hemodynamic consequences of IPF involves prostacyclin and NO.<sup>(15)</sup> Channick et al. reported that the inhalation of NO by an IPF patient with secondary pulmonary hypertension led to a significant fall in pulmonary-arterial pressure.<sup>(16)</sup> Of these novel therapies, we used NO with oxygen because NO was available, but the effect was not impressive.

The median survival for patients with IPF has been estimated to be 3 to 6 years,<sup>(7)</sup> but the course of childhood IPF is fulminant.<sup>(4,5)</sup> Children may be more vulnerable to lung parenchymal damage.<sup>(5)</sup> The most common cause of death from IPF is cor pulmonale due to pulmonary fibrosis, respiratory failure, or overwhelming pulmonary infections<sup>(7)</sup> as seen in our patient.

Idiopathic pulmonary fibrosis continues to pose a major clinical challenge because the pathogenesis and an effective therapy have yet to be determined.

We report on a 2-year-old boy with IPF treated using pulse steroid therapy without effect and who suffered catastrophic complications including sepsis followed by death. Open lung biopsy is vital for clinicians in order to determine a definitive diagnosis of IPF at an early stage and to allow an appropriate therapy to be instituted. The optimal use of steroids for IPF in children deserves further investigation, and it is worth trying new immunomodulatory therapies in the future.

## REFERENCES

1. Desmarquest P, Tamalet A, Fauroux B, Boule M, Boccon-Gibod L, Tournier G, Clement A. Chronic interstitial lung disease in children: response to high-dose intravenous methylprednisolone pulses. *Pediatr Pulmonol* 1998;26:332-8.
2. Turner-Warwick M, Burrows B, Johnson A. Cryptogenic fibrosing alveolitis: clinical features and their influence on survival. *Thorax* 1980;35:171-80.
3. Crystal R, Bitterman P, Rennard S, Hance A, Keogh B. Interstitial lung disease of unknown cause. Disorders characterized by chronic inflammation of the lower respiratory tract. *N Engl J Med* 1984;310:154-66.
4. Fan LL, Langston C. Chronic interstitial lung disease in children. *Pediatr Pulmonol* 1993;16:184-96.
5. Osika E, Muller MH, Boccon-Gibod L, Fauroux B, Sardet A, Grosskopf C, Couvreur J, Tournier G, Clement A. Idiopathic pulmonary fibrosis in infants. *Pediatr Pulmonol* 1997;23:49-54.
6. Coultas D, Zumwalt R, Black W, Sobonya R. The epidemiology of interstitial lung disease. *Am J Respir Crit Care Med* 1994;150:967-72.
7. Ryu JH, Colby TV, Hartman TE. Idiopathic pulmonary fibrosis: Current concepts. *Mayo Clin Proc* 1998;73:1085-101.
8. Nicod LP. Recognition and treatment of idiopathic pulmonary fibrosis. *Drugs* 1998;55:555-62.
9. Coker RK, Laurent GJ. Anticytokine approaches in pulmonary fibrosis: bringing factors into focus. *Thorax* 1997;52:294-6.
10. Wilborn J, Crofford LJ, Burdick MD, Kunkel SL, Strieter RM, Peters-Golden M. Cultured lung fibroblasts isolated from patients with idiopathic pulmonary fibrosis have a diminished capacity to synthesize prostaglandin E2 and to express cyclooxygenase-2. *J Clin Invest* 1995;95:1861-8.
11. McAnulty RJ, Laurent GJ. Pathogenesis of lung fibrosis and potential new therapeutic strategies. *Exp Nephrol* 1995;3:96-107.
12. Brown KK. Current management of idiopathic pulmonary fibrosis and predictors of outcome. In: King TE, editor. *New approaches to managing idiopathic pulmonary fibrosis*. American Thoracic Society 2000 Sept. p21-6.
13. Kramer MR, Berkman N, Mintz B, Godfrey S, Saute M, Amir G. The role of open lung biopsy in the management and outcome of patients with diffuse lung disease. *Ann Thorac Surg* 1998;65:198-202.
14. Ziesche R, Hofbauer E, Wittmann K, Petkov V, Block LH. A preliminary study of long-term treatment with interferon gamma-1b and low dose prednisolone in patients with idiopathic pulmonary fibrosis. *N Engl J Med* 1999;341:1246-9.
15. Egan JJ. New treatments for pulmonary fibrosis? *Lancet* 1999;354:1839-40.
16. Channick RN, Hoch RC, Newhart JW, Johnson FW, Smith CM. Improvement in pulmonary hypertension and hypoxemia during nitric oxide inhalation in a patient with end-stage pulmonary fibrosis. *Am J Respir Crit Care Med* 1994;149:811-4.

## 幼童原發性肺纖維病變

張魁文 吳昌騰 黃秀芬<sup>1</sup> 江東和 黃健榮

原發性肺纖維病變原因不明，雖然此病在幼童極為罕見，但是預後通常極差。此病在國內尚未被報告過。在此我們報告一個二歲幼童的原發性肺纖維病變以快速進行的呼吸困難繼發呼吸衰竭來表現，肺部切片證實為原發性肺纖維病變。雖然即時給予類固醇脈衝治療並嘗試使用一氧化氮治療，此病患仍然在住院後35天因持續低血氧死亡。原發性肺纖維病變應包含在呼吸困難的鑑別診斷中，並儘早給予類固醇治療。幼童原發性肺纖維病變給予類固醇的確實時機及劑量亦待研究，其他新式的藥物治療亦有待發展。(長庚醫誌 2003;26:60-4)

**關鍵字：**原發性肺纖維病變，類固醇脈衝治療。

---

長庚兒童醫院 台北院區 兒童內科部，病理部

受文日期：民國91年2月25日；接受刊載：民國91年5月3日。

索取抽印本處：黃健榮醫師，長庚兒童醫院 兒童內科部。桃園縣333龜山鄉復興街5-7號。Tel.: (03)3281200轉8218; Fax: (03)3288957