

## Aseptic Nonunion of a Femoral Shaft Treated Using Exchange Nailing

Chia-Wei Yu, MD; Chi-Chuan Wu, MD; Wen-Jer Chen, MD

**Background:** There are many methods for treating femoral shaft aseptic nonunions of which exchange nailing is the simplest technique. However, the reported success rate varies. Therefore, a prospective study was conducted to further clarify the role of exchange nailing.

**Methods:** From October 1994 through December 1999, 40 femoral shaft aseptic nonunions in 39 patients were treated using exchange nailing. The indications for this technique included a femoral shaft aseptic nonunion with a previously inserted intramedullary nail, less than 1 cm shortening, a radiolucent line of the nonunion, and no segmental bony defects. The surgical technique consisted of close removal of the previously inserted intramedullary nail, reaming the intramedullary canal as widely as possible (1 or 2 mm oversized), and re-insertion of a stable unlocked or locked intramedullary nail.

**Results:** Thirty-six femoral shaft aseptic nonunions in 35 patients were followed-up for at least 1 year (median, 2.9 years; range, 1.1~6.0 years) and 33 nonunions healed. The union rate was 91.7% (33/36) and the union period was median 4 months (range, 3~8 months). No major surgical complications were noted. The other three patients with persistent nonunions were continuously followed-up due to their reluctance for further operations.

**Conclusion:** Although exchange nailing is a relatively simple surgical technique, it can still achieve a high union rate with a low complication rate. Despite that factors to induce a persistent nonunion are still unclear, clinically, exchange nailing should be used as the first choice in the treatment of an indicated femoral shaft aseptic nonunion.

(*Chang Gung Med J* 2002;25:591-8)

**Key words:** femoral shaft, exchange nailing, aseptic nonunion.

Closed reamed unlocked or locked intramedullary nailing has been the treatment of choice in the treatment of closed or mild open femoral shaft fractures.<sup>(1-3)</sup> Usually, a high union rate with a low complication rate can be achieved. For severe open femoral shaft fractures, closed non-reamed unlocked

or locked intramedullary nails or initial external fixation with secondary reamed intramedullary nailing may be chosen.<sup>(4-7)</sup> Basically, performing closed intramedullary nailing requires the use of an image intensifier and a lot of equipment is needed. Therefore, open nailing is often performed, which

---

From the Department of Orthopedics, Chang Gung Memorial Hospital, Taipei.

Received: Feb. 1, 2002; Accepted: Jun. 17, 2002.

Address for reprints: Dr. Chia-Wei Yu, Department of Orthopedics, Chang Gung Memorial Hospital, 5, Fu-Shin Street, Kweishan, Taoyuan 333, Taiwan, R.O.C. Tel.: 886-3-3281200 ext. 2163; Fax: 886-3-3278113; E-mail: jeffyu11@yahoo.com.tw

consequently increases the rate of nonunion.<sup>(8-10)</sup>

To treat a femoral shaft aseptic nonunion, various surgical techniques can be used.<sup>(11-14)</sup> However, exchange nailing is the simplest technique among all of the treatment modalities. Some researchers have reported high rates of union with low complication rates.<sup>(15-18)</sup> In addition, in one study, a low union rate was found using this technique and the factors of failure were analyzed and reported.<sup>(19)</sup>

The use of exchange nailing is still controversial, although it only requires a small surgical wound, which can decrease blood loss and decrease risk of wound infection. Therefore, exchange nailing should not be abandoned casually. We conducted a prospective study to further define the role of exchange nailing. The advantages and disadvantages were also investigated.

## METHODS

From October 1994 through December 1999, 39 consecutive adult (> 15 years) patients with 40 femoral shaft aseptic nonunions were treated using exchange nailing at our institution. In this study, a union was clinically defined as no pain, no tenderness, and patients could walk without aids, and radiographically defined as solid callus with cortical density had bridged fracture fragments. A nonunion was defined as a fracture that had not healed after 1 year of treatment or a second operation was necessary to gain a union. The patients ranged in age from 18 to 73 years (median, 32 years) with a male to female ratio of 2:1. Causes of nonunions were due to failed treatment of acute fractures, which were all caused by vehicle crashes. Nonunion levels included upper third for 3 fractures, middle third for 33 fractures, and lower third for 4 fractures. All were closed fractures initially. These fractures had been treated operatively for 1~4 times during the interval of 0.5~9.0 years (median, 1.8 years). The previous implants consisted of plates and intramedullary nails. The techniques of the last operations included open Kuntschcr nailing for 16 fractures, open static locked nailing for 11, open dynamic locked nailing for 9, closed dynamic locked nailing for two, closed static locked nailing for one, and closed Kuntschcr nailing for one (Table 1). Five nonunions were associated with locked nail breakage (Cases 4,12,22,27,29), which included three cases after one-stage femoral

lengthening (Cases 4,12,29). All 40 nonunions were classified into the atrophic type because early stability was still sufficient which was deduced from the radiographs. Indications for this technique included femoral shaft aseptic nonunions with inserted intramedullary nails, nonunions with a radiolucent line, without segmental bony defects, and less than 1 cm shortening. History of wound healing process was carefully investigated and leg length discrepancy was evaluated using spinomalleolar distance with or without scanogram.

At admission, white blood cell count, erythrocyte sedimentation rate, and C-reactive protein were routinely checked to investigate for latent deep infection. There was no definite abnormal data for any patient in this study.

### Surgical technique

First, the patients were divided into two groups according to whether distal locked screws had to be inserted to achieve fragment stability.

For those with nonunions requiring no distal locked screw insertion, the patients were spinally anesthetized and placed on the operating table in the lateral decubitus position. A skin incision was made on the buttock and the previous implant was removed. The previous nail was removed. For a broken locked nail, it was removed using a hook retractor.<sup>(20)</sup> After a flexible guide wire was inserted into the distal fragment, the marrow cavity was reamed as widely as possible until strong resistance was felt. In these patients, only 1 or 2 mm over-reaming was performed and then a 1 mm smaller size of single Kuntschcr nail (Zimmer, Warsaw, Indiana, USA), double Kuntschcr nails or a proximally dynamic locked nail (Howmedica, Kiel, Germany) was inserted.

For those nonunions requiring distal locked screw insertion, patients were generally anesthetized with intubation and placed on the fracture table in the lateral decubitus position. A 2.4 mm Kirschner wire was inserted in the femoral condyle for skeletal traction. The previous implant was removed and a flexible guide wire was inserted. The marrow cavity was similarly reamed as widely as possible. Then, a 1 mm smaller size of locked nail with distal locked assembly was inserted. When 2 mm of over-reaming was performed and a 1 mm smaller sized locked nail was unavailable, a static locked nail was inserted.

Postoperatively, patients were permitted to ambulate with protected weight bearing as soon as possible. Quadriceps as well as knee range of motion exercise was encouraged. The patients were followed-up at the outpatient department at 4~6 week intervals. Clinical and radiographic fracture healing processes were recorded. Aids could be discontinued only when bony union had been achieved.

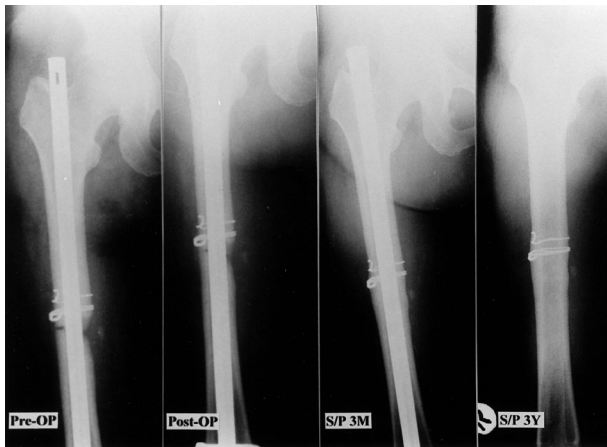
In this study, delayed union was not defined to avoid misrepresenting the union rate.

In order to assess whether the results of union or nonunion were associated with the fracture level, assembly of nails, or smoking history of the patients, the Chi-Square test and Fisher's exact test of independence were used.

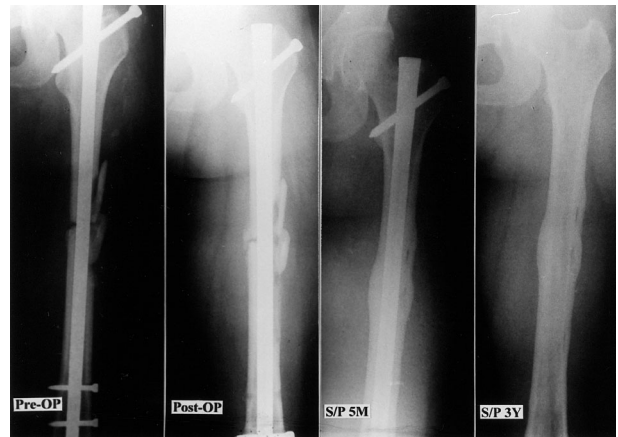## RESULTS

Thirty-five patients with 36 femoral nonunions were followed-up for at least 1 year (range, 1.1~6.0 years; median, 2.9 years). Four patients with four nonunions were lost to follow up despite all efforts. Thirty-three nonunions healed with a union rate of 91.7% (33/36) and a union period of median 4 months (range, 3~8 months, Figs. 1-3, Table 1).

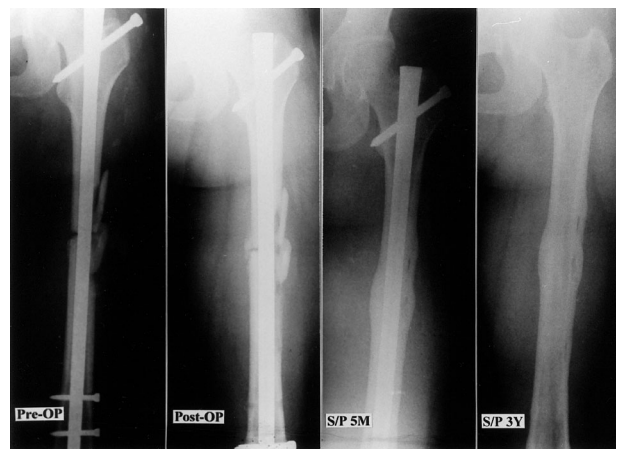There were no peri-operative complications and all patients were discharged within 5 days postoperatively.



**Fig. 1** Case 3 A 44-year-old woman sustained a right middle third femoral shaft fracture and was treated with open Kuntscher nailing at a local hospital. Nonunion occurred for 1 year and exchange nailing with a dynamic locked nail was performed. The nonunion healed uneventfully within 3 months.



**Fig. 2** Case 16 A 31-year-old man sustained a left middle third femoral shaft fracture and was treated with open static locked nailing at a local hospital. Nonunion occurred for 3.5 years and exchange nailing with a static locked nail was performed. The nonunion healed uneventfully within 5 months.



**Fig. 3** Case 39 A 36-year-old man sustained a left middle third femoral shaft fracture and was treated with closed static locked nailing at a local hospital. Nonunion occurred for 1.5 years and exchange nailing with a Kuntscher nail was performed. The nonunion healed uneventfully within 6 months.

Complications included three aseptic nonunions (8.3%). All three patients were followed-up only because no symptoms were noted and they hesitated to have further operations. There were no wound infections or malunions (angulation > 10 degrees, rotation > 10 degrees or shortening > 2 cm) noted.

**Table 1.** Clinical Data for 39 Patients with 40 Nonunions Treated with Exchange Nailing

Case No.	Age	Sex	Fracture Level	Previous Operation Times	Method of Last Operation	Interval from Injury (years)	Method of Treatment	Over-reaming (mm)	Union Period (months)	Complications	Follow-up (years)
1	18	M	B	1	CK	0.9	DL	1	4	---	6.0
2	31	M	B	1	CDL	4.5	DL	1	7	---	5.8
3	44	F	B	1	OK	1.0	DL	2	3	---	5.4
4	52	M	B	2	OSL	1.1	DL	2	4	---	5.0
5	62	M	B	1	OK	1.5	SL	2	T	T	T
6	26	M	B	1	OSL	2.0	DL	2	T	T	T
7	44	F	A	1	OK	2.0	DL	1	4	---	4.7
8	23	M	C	2	OSL	4.5	DL	1	N	N	4.5
9	73	M	B	1	ODL	3.0	SL	2	4	---	4.5
10	18	M	B	1	OK	0.8	DL	1	N	N	4.0
11	60	F	B	1	OK	2.0	K	1	T	T	T
12	19	M	A	2	OSL	8.0	DL	1	5	---	3.8
13	28	M	B	1	OK	1.5	K	1	4	---	3.5
14	66	M	B	2	ODL	2.0	DL	1	4	---	3.5
15	60	F	B	1	OK	1.8	SL	2	N	N	3.3
16	31	M	B	2	OSL	3.5	SL	1	5	---	3.3
17	22	M	A	2	ODL	3.0	DL	1	3.5	---	3.2
18	32	M	B	4	OK	2.0	K	1	4	---	3.0
19	28	M	B	1	OK	2.0	DL	2	3.5	---	3.0
20	60	M	B	1	ODL	1.6	DK	2	5	---	3.0
21	24	M	B	1	ODL	2.0	K	1	T	T	T
22	22	F	C	1	ODL	3.0	DL	1	6	---	2.9
23	36	M	B	1	OK	1.5	K	1	4	---	2.8
24	25	M	C	1	ODL	1.0	DL	2	8	---	2.8
25	73	M	B	1	OSL	5.0	DK	2	6	---	2.6
26	59	M	B	1	OK	0.6	DL	2	3.5	---	2.5
27	26	M	B	2	OSL	2.0	DL	2	4	---	2.4
28	40	M	B	1	OK	1.0	DK	2	4	---	2.4
29	36	M	B	4	OSL	9.0	DK	1	4	---	2.2
30	39	F	B	1	OSL	1.0	SL	1	5	---	2.0
31	61	M	B	3	OSL	3.0	DK	1	4	---	1.8
32	61	M	C	3	ODL	3.0	DL	2	4	---	1.8
33	38	F	B	1	OK	0.5	DL	1	6	---	1.7
34	29	F	B	1	CDL	3.0	K	1	5	---	1.6
35	25	M	B	1	OK	1.2	K	1	4	---	1.6
36	32	F	B	1	ODL	1.8	DL	2	4	---	1.5
37	24	F	B	1	OSL	1.0	SL	2	4	--	1.4
38	56	F	B	1	OK	0.8	DL	1	5	--	1.3
39	36	M	B	1	CSL	1.5	K	1	6	--	1.2
40	26	F	B	1	OK	0.6	DL	1	3.5	---	1.1

A: upper third; B: middle third; C: lower third; CDL: closed dynamic locked nailing; CK: closed Kuntscher nailing; CSL: closed static locked nailing; DK: double Kuntscher nailing; DL: dynamic locked nailing; F: female; K: Kuntscher nailing; M: male; ODL: open dynamic locked nailing; OK: open Kuntscher nailing; OSL: open static locked nailing; N: nonunion; SL: static locked nailing; T: lost to follow-up.

Case numbers 31,32, identical patient with bilateral nonunions.

The fracture levels of the three patients with persisted nonunion were two in the middle third and one in the distal third. The three cases with proximal third nonunions all achieved union after exchange nailing procedures. The numbers of patients of nonunion/union were 0/3 in the proximal third, 2/27 in the middle third, and 1/3 in the distal third. There were no significant differences ( $X^2=1.806$ ,  $p>0.05$ , Chi-Square test) between the different fracture levels in the results of union or nonunion.

One of the five cases using static nails and two of the thirty-one cases using dynamic nails had persisted nonunion. The numbers of patients of nonunion/union were 1/4 in the static nail group and 2/29 in the dynamic nail group. The  $p$ -value was 0.326 using the Fisher's exact test. There were no significant differences between the different kinds of the assembled nails in the results of union or nonunion.

In the 20 patients with smoking history, 18 of them achieved union and two had persisted nonunion. In the 16 patients without the history of smoking, one had persisted nonunion. The numbers of patients of nonunion/union were 2/18 in the smoking group and 1/15 in the non-smoking group. The  $p$ -value was 0.426 using the Fisher's exact test. There were no significant differences between the patients with or without smoking history in the results of union or nonunion.

No statistical differences were found for nonunion types (all were atrophic), fracture levels (proximal: middle: distal=0/3: 2/27: 1/3,  $X^2=1.806$ ,  $p>0.05$ , Chi-Square test), assembly of nails (static: dynamic=1/4: 2/29,  $p=0.326$ , Fisher's exact test), or smoking history (smoking: non-smoking=2/18: 1/15,  $p=0.426$ , Fisher's exact test) as described in the literature.

## DISCUSSION

A nonunion is traditionally classified into either a hypertrophic or atrophic type for the convenience of treatment. The former is usually due to loss of fracture stability and the latter, loss of osteogenic power. The principle of treatment should depend on the type of nonunion to provide either stability or osteogenic power. During the past several years, methods for nonunion treatment have continuously developed.<sup>(21-27)</sup> Various nonoperative or operative

techniques are available. However, maintenance of sufficient stability with supplementation of cancellous bone grafts has been the most convincing and has achieved the highest success rate. According to reports in the literature, exchange nailing that provides internal bone grafts have been reported to be superior to open bone grafting.<sup>(28-30)</sup>

The reported success rate of exchange nailing to treat femoral shaft delayed unions or nonunions is 53~100%.<sup>(12,19,20,28)</sup> The advantages of exchange nailing have been advocated. Due to the small incision wound for nail inlet and no exploration of the nonunion site, operating time can be shortened and decrease the complication rate. However, the maximal size of bone defects suited for this technique has not yet been clarified. Clinically, it seems to be impossible to use patients for testing. Factors favoring fracture healing are minimal gap, adequate stability, and sufficient nutrient supply.<sup>(21)</sup> The size of bone defects can affect the union rate. Therefore, if there is any doubt, open bone grafting should be performed.<sup>(28,31)</sup> In this study, only nonunions with a radiolucent line were treated and a 91.3% success rate was achieved. On the other hand, no detailed descriptions about bone defects were included in the previous series. Theoretically, the amount of reaming bone graft should be not copious and the size of the bone defects will affect the union rate.

When a nonunion occurs and a radiolucent line is noted, the gap should be occupied by the connective tissues. Over-reaming of 1 or 2 mm can only deposit a small amount of cancellous bone along the reamed tract. Theoretically, fracture level will not affect the deposit of bone graft. In this study and in reports in the literature, the results were concordant.<sup>(12,19)</sup> Fracture level is not related to persistent nonunions. On the other hand, only over-reaming 1 or 2 mm of the marrow cavity can also achieve a high union rate. The amount of bone graft does not need too much.

Although a dynamic locked nail can provide the compressive force and promotes fracture healing, there is no difference between a static and dynamic mode of exchange nailing.<sup>(12)</sup> With cancellous bone grafts to promote fracture healing, the added compressive force does not seem to be so critical. Results of this study and the reports in the literature also show the same viewpoints.

Using a reamed intramedullary nail to treat a

femoral shaft fracture usually can achieve sufficient stability. Except for when Kuntscher nail migration or nail breakage occurs in the early stage, all nonunions should be classified into the atrophic type. Therefore, cancellous bone grafting is always necessary to provide osteogenic power. In this study, all nonunions were classified into the atrophic type, which was different from the previous series.<sup>(12,19)</sup> In some reports in the literature, classifying a nonunion only depended on the callus amount on the radiograph which was often mis-representative. Thus, fragment stability should also be considered for classification.<sup>(21,28)</sup>

Patients with persistent nonunions in this study were questioned as to history of smoking. Two patients denied smoking and one admitted to smoking. Although smoking has been considered to interfere with fracture healing or nonunion treatment in reports in the literature, no differences were noted in this study.<sup>(32,33)</sup> The effects of smoking on fracture healing has also been doubted by some researchers in reports in the literature.

The methods for treatment of persistent nonunion after exchange nailing are many and all methods have individual advantages and disadvantages. Repeated exchange nailing has been reported with success and the technique is the simplest. However, due to a relatively small sample size, the definite effects should be re-evaluated.<sup>(12)</sup> Open bone grafting may be considered and the effects have been satisfactory.<sup>(28)</sup> As for conversion to plating, a large wound with extensive soft tissue dissection may introduce more complications.<sup>(11,34)</sup> In our opinion, plating should be preserved in the distal femur where a locked nail easily breaks.<sup>(35)</sup>

Exchange nailing may also be used to treat infected nonunion and success has been reported in the literature.<sup>(36)</sup> However, after all, reaming introduces cortical necrosis. If sequestrum is produced, deep infections are hard to control. Therefore, the reaming should be very slow and antibiotic powder may be placed into the marrow cavity for local control. In principle, exchange nailing should not be used in patients with acute infections. For those with acute infections, staged operations with conversion to external fixation may be more suitable.<sup>(31,36)</sup>

In conclusion, the present study has revealed that exchange nailing can achieve a high success rate in the treatment of femoral shaft aseptic nonunions

with indications. From theoretical and clinical considerations, it is the simplest technique among various treatment modalities and has the lowest complication rate. Therefore, it should be considered as the treatment of choice for indicated cases of nonunions. Because the nonunion rate using this technique is so low, the factors that induce the persistent nonunion cannot be concluded from this study. Relatively larger sample sizes are necessary to investigate the factors and clinical outcomes. However, it seems to be very difficult to collect sufficient numbers of cases for such a study.

## REFERENCES

1. Wolinsky PR, McCarty E, Shyr Y, Johnson K. Reamed intramedullary nailing of the femur: 551 cases. *J Trauma* 1999;46:392-9.
2. Krpfl A, Naglik H, Primavesi C, Hertz H. Unreamed intramedullary nailing of femoral fractures. *J Trauma* 1995;38:717-26.
3. Herscovici D Jr, Ricci WM, McAndrews P, DiPasquale T, Sanders R. Treatment of femoral shaft fracture using unreamed interlocked nails. *J Orthop Trauma* 2000;14:10-4.
4. Brumback RJ, Ellison PS Jr, Poka A, Lakatos R, Bathon GH, Burgess AR. Intramedullary nailing of open fractures of the femoral shaft. *J Bone Joint Surg [Am]* 1989;71:1324-31.
5. Grosse A, Christie J, Taglang G, Court-Brown C, McQueen M. Open adult femoral shaft fracture treated by early intramedullary nailing. *J Bone Joint Surg [Br]* 1993;75:562-5.
6. Brien PJ, Meek RN, Powell JN. Primary intramedullary nailing of open femoral shaft fractures. *J Trauma* 1991;31:113-6.
7. Riska EB, von Bonsdorff H, Hakkinen S, Jaroma H, Kiviluoto O, Paavilainen T. Primary operative fixation of long bone fractures in patients with multiple injuries. *J Trauma* 1977;17:111-21.
8. Chao EYS, Inoue N, Elias JJ, Aro H. Enhancement of fracture healing by mechanical and surgical intervention. *Clin Orthop* 1998;355S:163-78.
9. Kempf I, Grosse A, Beck GF. Closed locked intramedullary nailing: its application to comminuted fractures of the femur. *J Bone Joint Surg [Am]* 1985;67:709-20.
10. Winkquist RA, Hansen ST, Clawson DK. Closed intramedullary nailing of femoral fractures. *J Bone Joint Surg [Am]* 1984;66:529-39.
11. Carlo B, William MR, Brett RB. Results of indirect reduction and plating of femoral shaft nonunions after intramedullary nailing. *J Orthop Trauma* 2001;15:254-63.
12. David JH, Stanley SL, James AG. Success of exchange

- reamed intramedullary nailing for femoral shaft nonunion or delayed union. *J Orthop Trauma* 2000;14:178-82.
13. Ueng SWN, Chao EK, Lee SS, Shih CH. Augmentative plate fixation for the management of femoral nonunion after intramedullary nailing. *J Trauma* 1997;43:640-4.
  14. Ring D, Jupiter JB, Sanders RA, Quintero J, Santoro VM, Ganz R, Marti RK. Complex nonunion of fractures of the femoral shaft treated by wave-plate osteosynthesis. *J Bone Joint Surg [Br]* 1997;79:289-94.
  15. Brav EA. The use of intramedullary nailing for nonunion of the femur. *Clin Orthop* 1968;60:69-75.
  16. Kempf I, Grosse A, Rigaut P. The treatment of noninfected pseudarthrosis of the femur and tibia with locked intramedullary nailing. *Clin Orthop* 1986;212:142-54.
  17. Oh I, Nahigian SH, Rascher JJ, Farrall JP. Closed intramedullary nailing for ununited femoral shaft fractures. *Clin Orthop* 1975;106:206-15.
  18. Webb LX, Winquist RA, Hansen ST. Intramedullary nailing and reaming for delayed union of the femoral shaft. *Clin Orthop* 1986;212:133-41.
  19. Weresh MJ, Hakanson R, Stover MD, Sims SH, Kellam JF, Bosse MJ. Failure of exchange reamed intramedullary nails for ununited femoral shaft fractures. *J Orthop Trauma* 2000;14:335-8.
  20. Wu CC, Shih CH, Chen WJ, Tai CL. Treatment of ununited femoral shaft fractures associated with locked nail breakage: comparison between closed and open revision techniques. *J Orthop Trauma* 1999;13:494-500.
  21. Wu CC. The effect of dynamization on slowing the healing of femur shaft fractures after interlocking nailing. *J Trauma* 1997;43:263-7.
  22. Abeed RI, Naseer M, Abel EW. Capacitively coupled electrical stimulation treatment: results from patients with failed long bone fracture unions. *J Orthop Trauma* 1998;12:510-3.
  23. Matelic TM, Monroe MT, Mast JW. The use of endosteal substitution in the treatment of recalcitrant nonunions of the femur: report of seven cases. *J Orthop Trauma* 1996;10:1-6.
  24. Ryaby JT. Clinical effects of electromagnetic and electric fields on fracture healing. *Clin Orthop* 1998;355S:205-15.
  25. Bhandari M, Schemitsch EH. Clinical advances in the treatment of fracture nonunion: the response to mechanical stimulation. *Curr Orthop* 2000;11:372-7.
  26. Wang CJ, Chen HS, Chen CE, Yang KD. Treatment of nonunions of long bone fractures with shock waves. *Clin Orthop* 2001;381:95-101.
  27. Nolte PA, van der Krans A, Patka P, Janssen IMC, Ryaby JP, Albers GHR. Low-intensity pulsed ultrasound in the treatment of nonunions. *J Trauma* 2001;51:693-703.
  28. Wu CC, Chen WJ. Treatment of femoral shaft aseptic nonunions: comparison between closed and open bone-grafting techniques. *J Trauma* 1997;43:112-6.
  29. Chapman MW. The effect of reamed and nonreamed intramedullary nailing on fracture healing. *Clin Orthop* 1998;355S:230-8.
  30. Perry CR. Bone repair techniques, bone graft, and bone graft substitutes. *Clin Orthop* 1999;360:71-86.
  31. Wei FC, El-Gammal TA, Lin CH, Ueng WN. Free fibula osteoseptocutaneous graft for reconstruction of segmental femoral shaft defects. *J Trauma* 1997;43:784-92.
  32. Ahmad A, Saleh M, Hashmi M. Effects of smoking on healing of nonunions in long bones. *J Bone Joint Surg [Br]* 2001;83:230.
  33. Schmitz MA, Finnegan M, Natarajan R, Champine J. Effect of smoking on tibial shaft fracture healing. *Clin Orthop* 1999;365:184-200.
  34. Wu CC. Treatment of femoral shaft aseptic nonunion associated with plating failure: emphasis on the situation of screw breakage. *J Trauma* 2001;51:710-3.
  35. Chapman MW, Finkemeier CG. Treatment of supracondylar nonunions of the femur with plate fixation and bone graft. *J Bone Joint Surg [Am]* 1999;81:1217-28.
  36. Wolinsky P, Tejwani N, Richmond JH, Koval KJ, Egol K, Stephen DJG. Controversies in intramedullary nailing of femoral shaft fractures. *J Bone Joint Surg [Am]* 2001;83:1404-15.

## 更換骨髓內釘治療股骨幹非感染性不癒合之研究

游家偉 吳基銓 陳文哲

- 背景：** 雖然治療股骨幹非感染性不癒合的方法有許多種，更換骨髓內釘仍然被認為是最簡單的手術法。然而，癒合的成功率在不同的研究計畫中仍有相當的差異，本研究採取更換骨髓內釘於治療股骨幹非感染性不癒合，評估其臨床追蹤結果，以更進一步確立其所扮演之角色。
- 方法：** 從1994年10月至1999年12月，39位患有股骨幹非感染性不癒合之患者（其中一位為兩側股骨幹不癒合）接受此項手術法治療。手術之適應症為：股骨幹非感染性不癒合、已接受骨髓內釘固定、股骨縮短小於1公分、X光檢查於不癒合處顯示放射線透過性、並且無間段式骨骼缺損。手術方式包括：拔除原有之骨髓內釘、骨髓內腔擴大鑽孔、以及重新置放較穩定之骨髓內釘。
- 結果：** 這些患者接受手術治療之後，有35位病患（包括一例兩側疾患）接受臨床追蹤至少壹年（正中期2.9年，分布範圍1.1到6.0年）；其中有32位病患之股骨順利地癒合（包括一例兩側疾患），癒合率為91.7%（33/36），癒合的正中期為4個月（分布範圍3到8個月），並且沒有產生任何嚴重的手術併發症。另外的三位股骨持續不癒合之病患，目前仍繼續接受臨床追蹤，尚未接受進一步手術治療。
- 結論：** 在本研究中採用更換骨髓內釘手術法用於治療股骨幹非感染性不癒合，雖然手術技術相對來說較簡單，但是依舊可以達成很高的癒合率，而產生手術併發症的機率亦相當低；雖然造成持續不癒合的因素仍然不明，但是，臨床上，對於符合上述手術適應症之患者，更換骨髓內釘手術法應被接受為治療股骨幹非感染性不癒合之優先選擇。
- （長庚醫誌 2002;25:591-8）

**關鍵字：** 股骨幹，更換骨髓內釘，非感染性不癒合。