

## Facial Reconstruction after a Complicated Gunshot Injury

Vanna Long, MD; Lun-Jou Lo, MD; Yu-Ray Chen, MD

Facial gunshot injuries are unusual and complicated clinical entities. Because of the mechanism of injury, early aggressive primary reconstruction might not be ideal. Initial conservative management followed by staged secondary reconstruction could be performed to obtain satisfactory functional and aesthetic results. Reconstruction of the cranio-maxillo-facial deformities requires a multi-disciplinary approach, the same way as for patients with cleft lip/palate deformities. We present a male patient with severe facial gunshot injuries. A team approach revealed maxilla recession, dental malocclusion, a large oronasal fistula over his hard palate, velopharyngeal insufficiency, and a stable psychosocial status. His main concern was facial appearance, which included the nose, lip, and scars. Staged reconstructions were performed, consisting of orthognathic surgery, rhinoplasty, lip-switch flap, and revisions of scars. A satisfactory outcome was obtained. The results indicated the importance of preoperative evaluation and treatment planning for this uncommon problem. (*Chang Gung Med J* 2002;25:557-62)

**Key words:** gunshot injury, facial reconstruction, multidisciplinary management.

Facial gunshot injuries are uncommon and complex, thus they require careful planning for reconstructive surgery. Standard treatment protocols were lacking except for the resuscitation purposes. The severity of the facial gunshot injuries varies according to the caliber of the weapon used and to the distance from which the patient sustained the injury. Close-range, high-velocity gunshot wounds can result in devastating functional and aesthetic consequences for the surviving patients. Early management of these patients should focus on resuscitation, with paramount attention given to opening the airway. Bleeding from the injury and the subsequent swelling can significantly compromise the airway. Control with either an endotracheal tube or tracheostomy should be considered early. Hemodynamic resuscitation should be performed followed by thorough patient evaluation to rule out concomitant injuries.

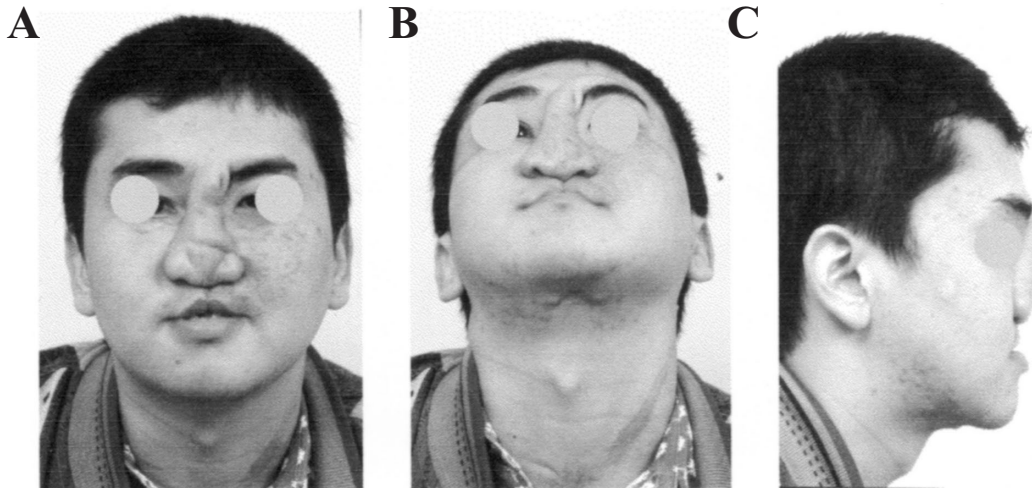
Subsequent management for the patients becomes controversial in terms of surgical reconstruction for facial functions and aesthetics. Series have been reported in the literature advocating early aggressive intervention for one stage reconstruction of all involved structures.<sup>(1-5)</sup> The advantages of early aggressive reconstruction are ease of tissue mobilization, reduced tissue fibrosis, and reduced period of facial deformity. Because of the severity of injury and uncertain margins of tissue damage, papers were also published favoring initial conservative approach and advocating primary non-operative management for the injury.<sup>(3,6)</sup> This extended to include angiographic management of bleeding problems and closed treatment of skeletal injuries.<sup>(7,8)</sup> Reconstructions are often performed as secondary intentions. The secondary deformity of the facial gunshot injury may include skeletal as well as soft tissues covering the cranium, orbits, nose, and maxil-

---

From the Department of Plastic and Reconstructive Surgery, Chang Gung Memorial Hospital, Taipei.

Received: Aug. 31, 2001; Accepted: Dec. 12, 2001

Address for reprints: Dr. Lun-Jou Lo, Department of Plastic and Reconstructive Surgery, Chang Gung Memorial Hospital, 5, Fushin Street, Kweishan, Taoyuan 333, Taiwan, R.O.C. Tel.: 886-3-3281200 ext.2855; Fax: 886-3-3285818; E-mail: lunjoulo@ms1.hinet.net



**Fig. 1** The patient before surgical reconstruction, views A to C. He has recessed midface, nasal deformity with depressed tip, displaced right medial canthus, and tight and scarred upper lip. There is a scar under the chin showing inlet of the gunshot wound, and a scar at the lower neck due to tracheostomy.

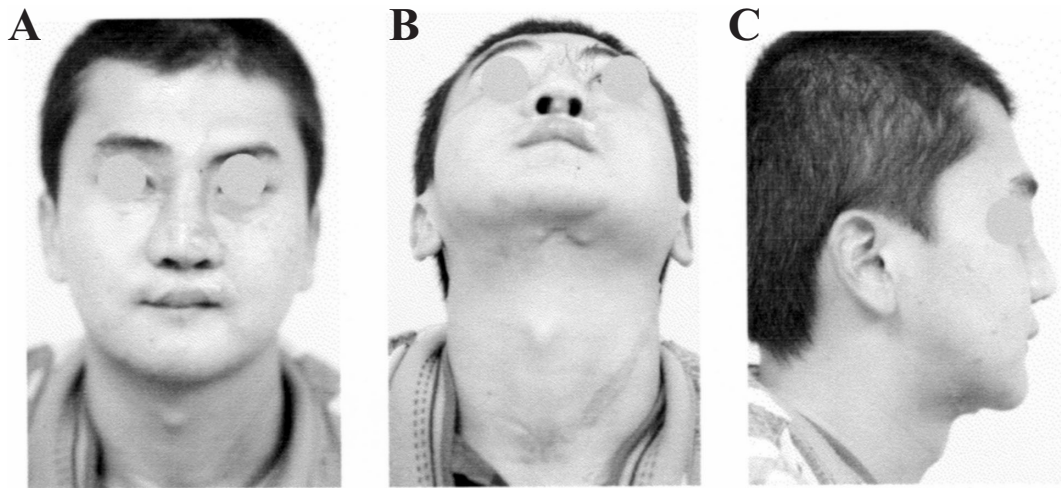
lo-mandible areas. As such, the treatment requires multi-disciplinary evaluation and planning. We presented a rare case with extensive facial deformity resulting from close-range high-velocity gunshot injury.

### CASE REPORT

A 22-year-old man came to our craniofacial center with severe secondary facial deformities. He was a retired soldier who suffered from a gunshot injury through the chin upward due to a suicide attempt 18 months ago. Multiple surgical procedures had been performed at another hospital, and the results were not satisfactory. On examination, he was alert but quiet, and had stable vital signs (Fig. 1). His nose was depressed and covered with a down-turned forehead flap. The nostrils were flat and wide. The right inner canthal area was inferiorly displaced. The midface was recessed with an injured and defective maxilla. A large hole was present in the hard palate area. He had class III dental malocclusion with loss of multiple teeth. His upper lip was tight with a lack of philtral and Cupid's bow definitions. Perceptual speech evaluation revealed hypernasality with acceptable intelligibility. Further evaluation revealed stable psychological status with a strong desire for facial reconstruction. His family supported him both

economically and psychologically. Dental evaluation including cephalographic and panoramic views revealed a disproportional maxillo-mandibular relationship and the aforementioned dento-osseous problems. Ophthalmic and otolaryngological evaluation disclosed nothing other than the problems mentioned earlier. The multidisciplinary evaluation developed a treatment plan including, in the sequence, orthognathic surgery, orthodontic management, closure of oronasal fistula and velopharyngeal surgery, lip and nasal reconstructive surgery, and scar revision.

In August 1996, the patient received Le Fort I osteotomy to advance maxilla 5 mm on the right, 8 mm on the left side, and a 2-segment Kole osteotomy to setback and correct the jaw deformity. The operation was uneventful and intermaxillary fixation was removed in 4 weeks. He rejected the recommended reconstruction for the palatal fistula and velopharyngeal insufficiency. In January 1997, he was admitted for Abbe flap operation, nasal skin revision for forehead flap deformity, and medial canthal reconstruction. The Abbe flap was divided in 2 weeks. Three months later, he received open tip rhinoplasty with rib cartilage graft and revision cheiloplasty. The nose dissection was difficult because of the tissue fibrosis and contraction. The rib cartilage graft was used for the nasal dorsum and tip augmentation. Postoperative wound healing was smooth with no



**Fig. 2** The patient after multiple surgical reconstructions, views A to C, showing satisfactory correction of the facial osseous and soft tissues.

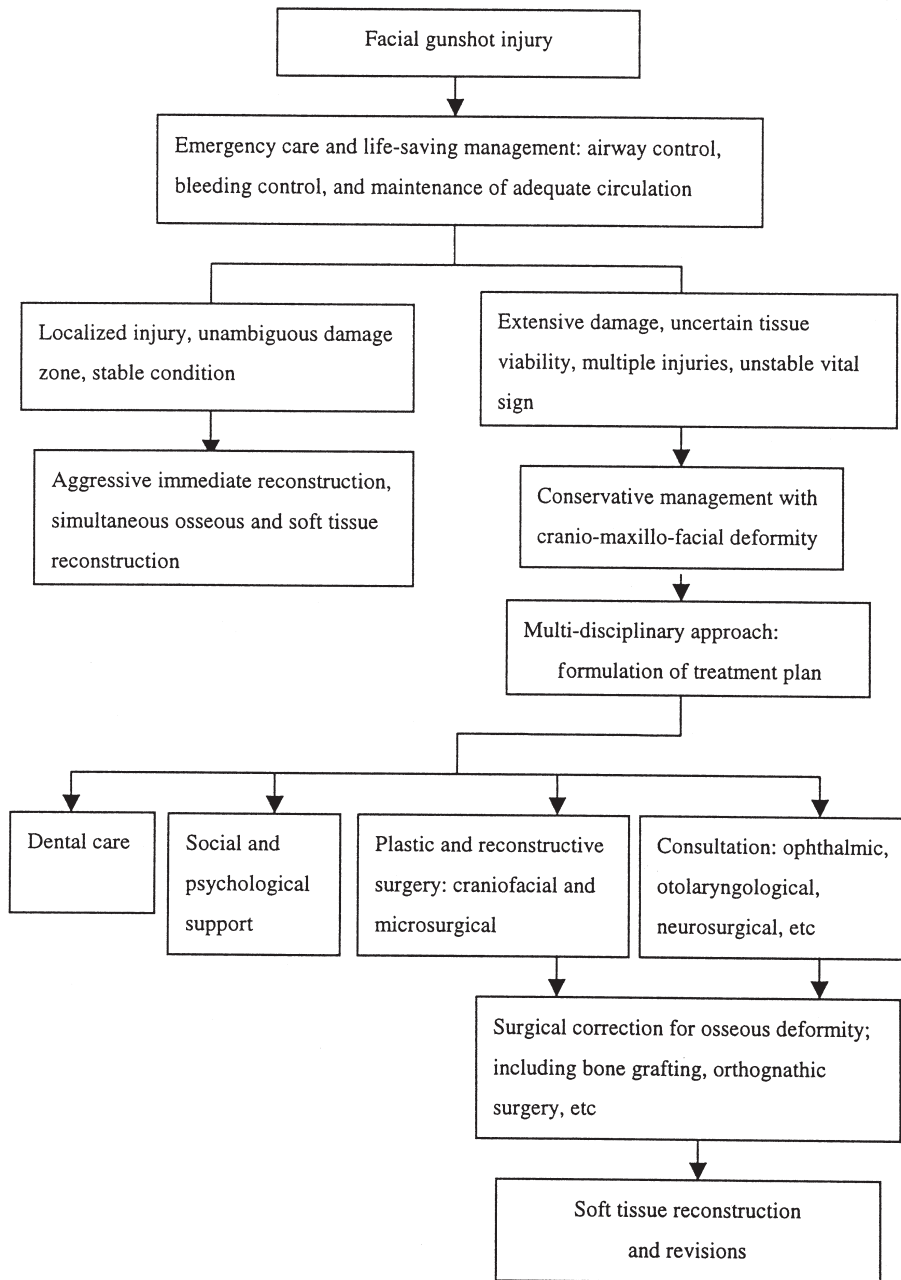
complications. The operations successfully corrected the lip and nasal deformities. He subsequently received touch-up surgeries for facial scars, z-plasty, and fascia-fat graft due to facial depressions. The patient was happy with the surgical outcome (Fig. 2), and did not wish further revision.

## DISCUSSION

Gunshot injuries are uncommon problems, except in wartime or in certain areas.<sup>(9,10)</sup> Patients may suffer injury to the underlying craniofacial skeleton, airway compromise, intracranial injury, and great vessel injuries, which may require urgent surgical treatment.<sup>(11)</sup> Craniofacial trauma associated with gunshot injury typically involves both functional and aesthetic deformities, leading to mental and social problems. Immediate reconstruction or serial debridement and delayed closure for secondary reconstruction have been advocated. For some patients with localized damage and few complex deformities, immediate surgery with bone and soft tissue reconstruction is indicated to obtain rapid recovery. However in most severe gunshot injuries, the damage and deformities are complicated and extensive, thus require prolonged care and management. These problems are challenging and involve multidisciplinary evaluation and treatment planning.

Based on our extensive experience on treating cleft facial deformities, we would like to formulate the treatment protocol (Fig. 3) for patients with this kind of traumatic facial deformity. The decision whether to take early aggressive management or staged secondary reconstruction depends on individual patient's situation as well as extrinsic factors. The extrinsic factors involve the surgeon's ability and experience, hospital facility, and availability of the treatment team. For patients with localized gunshot facial injuries, unambiguous damaged zones, and stable vital signs, an aggressive immediate management and reconstruction is mandatory. Conservative and staged reconstruction strategy is reserved for patients suffering from extensive damage with uncertain tissue viability, multiple injuries, and unstable vital signs. It is to be noted that an optimal outcomes occur due to appropriate treatment planning and a well-experienced treatment team.

This patient came to us with severe secondary facial deformity from a gunshot injury. The initial treatment had been performed elsewhere, and hence our planning focused on secondary reconstructions. A general principle for reconstruction planning is from the interior to exterior, from function to aesthetics, and from osseous to soft tissues. Our patient was evaluated using various specialties for formulation of a treatment plan. Psychosocial assessment was



**Fig. 3** Treatment protocol for facial gunshot injury

indispensable for the comprehensive reconstruction. The plan was to perform orthognathic surgery to normalize maxillo-mandibular relationship, upon which the nose and lip deformities were to be reconstructed. Rigid internal fixation for the skeletal parts

helped minimize relapse. Had the patient agreed to receive surgical reconstruction for palatal defect and oronasal fistula, a free tissue transfer may have been indicated. Although his speech was hypernasal, the articulation and intelligibility were acceptable. Rib

graft for nasal reconstruction is more resistant to infection as compared to allograft, which worked well in this patient. An Abbe flap transferred to the midline of the upper lip effectively released the lip tension, improved lip balance, and provided philtral definition. Staged reconstruction for this patient was indicated because of the condition of the osseous and soft tissues.

In conclusion, facial gunshot injuries should be managed as other types of facial traumas with initial resuscitation and wound care. Either immediate aggressive reconstruction or delayed secondary reconstruction depends on the patient's condition, the wound status, and the surgeon's judgment. The planning of staged reconstructions for severe secondary facial deformities was discussed and illustrated in our patient. The experience has been that carefully planned and timed surgical intervention will lead to the best results.

## REFERENCES

1. Mladick RA, Georgiade NG, Rover J. Immediate flap reconstruction for massive gunshot wounds of the face. Case report. *Plast Reconstr Surg* 1970;45:186-8.
2. Gruss JS, Antonyshyn O, Phillips JH. Early definitive bone and soft-tissue reconstruction of major gunshot wounds to the face. *Plast Reconstr Surg* 1991;87:436-50.
3. Kihitir T, Ivatury RR, Simon RJ, Nassoura Z, Leban S. Early management of civilian gunshot wounds to the face. *J Trauma* 1993;35:569-75.
4. Guiliani G, Anile C, Massarelli M, Maira G. Management of complex craniofacial trauma. *Reb Stomatol Chir Maxillofac* 1997;98:100-2.
5. Greenberg AM. Management of facial fractures. *NY State Dent J* 1998;64:42-7.
6. MacFarlane C. Management of gunshot wounds. The Johannesburg experience. *Int Surg* 1999;84:93-8.
7. Sclafani S, Panetta T, Goldstein A. The management of arterial injuries caused by penetration of zone III of the neck. *J Trauma* 1985;25:871-81.
8. Keller A. The management of gunshot fracture of the humerus. *Injury* 1995;26:93-6.
9. Thorne CH. Gunshot wounds to the face. Current concepts. *Clin Plast Surg* 1992;19:233-44.
10. Taher AA. Management of weapon injuries to the craniofacial skeleton. *J Craniofac Surg* 1998; 9:371-82.
11. Hollier L, Grantcharova EP, Kattash M. Facial gunshot wounds: a 4-year experience. *J Oral Maxillofac Surg* 2001;59:277-82.

## 複雜性槍傷後顏面重建

龍威耀 羅綸洲 陳昱瑞

顏面槍傷是一項少見但複雜的臨床問題，因為其特殊的傷害機制，早期積極性的一次性重建可能不是最理想的方法。初期保守性處理，然後利用分期式二次性重建可以得到功能上及美觀上滿意的結果。顱顎顏部位缺損的重建需要多部門的團隊合作，型式與唇顎裂病人的重建相同。這裏報告一個嚴重槍傷畸形的男性病人，經由團隊評估顯示上顎後縮，牙齒咬合異常，硬顎一個大洞，顎咽閉鎖不全，然而心理社會狀態穩定。他主訴顏面外觀不正常要求改善，經過幾次手術，包括正顎手術，鼻矯正術，唇瓣移轉術，和修疤術，得到滿意的外觀。此結果顯示對此罕見的問題需要仔細的術前評估以及治療計畫擬定。(長庚醫誌 2002;25:557-62)

**關鍵字：**槍傷，顏面重建，團隊治療。