

## Minimally Invasive Surgery for Coronary Artery Disease with Associated Lung Cancer

Hung-I Lu, MD; Yi-Cheng Wu, MD; Ming-Ju Hsieh, MD; Hui-Ping Liu, MD;  
Pyng Jing Lin MD

Simultaneous surgical management of patients with co-existing ischemic heart disease and lung carcinoma remains controversial. Traditionally, these operations have been staged, with coronary artery revascularization first, followed by pulmonary resection at a later date. Under this procedure, tumor resection is delayed, and these staged procedures may increase morbidity and cost. Our experience with minimally invasive surgery in the cardiac and thoracic fields suggests that both diseases can be resolved within the same operation. This report presents a 65-year-old man with coronary artery disease (CAD), and left lung cancer. He received concomitant coronary artery bypass grafting for CAD and pulmonary resection for lung cancer via a left parasternal minithoracotomy. No complaints or clinical signs were observed during a 6 month follow-up. Therefore, major cardiac and thoracic procedures that are performed via a minimally invasive approach using conventional instruments, can result in a safer, quicker, and more economical procedure. The results of the a minimally invasive approach demonstrated the technical feasibility of treating a triple vessel cardiac disease with lung cancer. (*Chang Gung Med J* 2002;25:110-4)

**Key words:** minimally invasive surgery, coronary artery disease, lung cancer.

Simultaneous surgical management of patients with co-existing ischemic heart disease and lung carcinoma remains controversial. Traditionally, there has been generalized reluctance to perform a pulmonary operation at the same time as a cardiac procedure that requires extracorporeal circulation, presumably because of coagulation defects related to heparinization and limited pulmonary exposure. However, delayed tumor resection may carry a high risk of metastasis for the individual patient and increase morbidity and cost. Despite the adverse effects of cardiopulmonary bypass and systemic heparinization, several reports have implied that concomitant cardiac surgery and non-cardiac procedures can be performed successfully and safely.<sup>(1,2)</sup> Our

experience with minimally invasive surgery in the cardiac and thoracic fields also indicates that both problems can be addressed during the same operation. This report presents our experience with concomitant coronary artery bypass graft (CABG) and pulmonary resection for lung cancer using a minimally invasive procedure.

### CASE REPORT

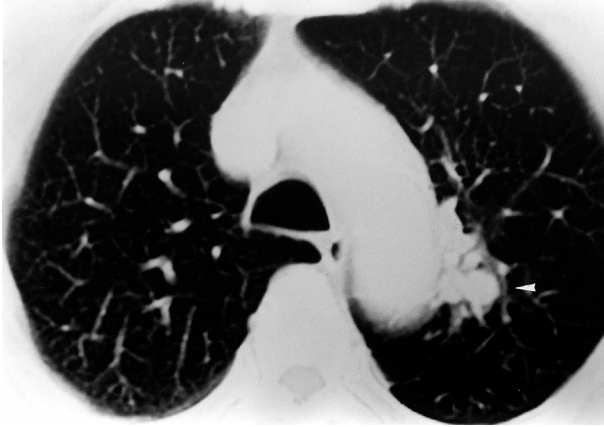A 65-year-old man was admitted to Chang Gung Memorial Hospital with an incidental finding of left upper lung mass. The patient reported good performance status before admission. His physical examination was unremarkable. Baseline forced

---

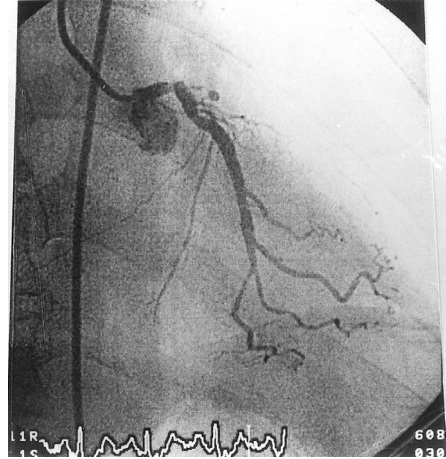
From the Division of Thoracic & Cardiovascular Surgery, Chang Gung Memorial Hospital, Taipei; Chang Gung University, Taoyuan.

Received: Feb. 14, 2001; Accepted: Jun. 11, 2001

Address for reprints: Dr. Yi-Cheng Wu, Division of Thoracic & Cardiovascular Surgery, Chang Gung Memorial Hospital, 5, Fushin Street, Kweishan, Taoyuan, 333, Taiwan, R.O.C. Tel.: 886-3-3281200 ext. 2118; Fax: 886-3-3285818; E-mail: chenh2118@cgmh.org.tw



**Fig. 1** Computed tomography demonstrates a periaortic nodular lesion at left upper lung (arrow head) with surrounding lung infiltration.



**Fig. 2** Cardiac catheterization demonstrates 60% stenosis of the left main coronary artery and total occlusion of the left anterior descending coronary artery.

vital capacity (FVC) and forced expiratory volume 1 s (FEV<sub>1</sub>) were 3.22 L and 2.59 L/s, respectively (101.6% and 112.6% predicted, respectively). Contrast computerized tomography of the thorax demonstrated a 1.2 cm lesion in the left upper lobe without significant hilar or mediastinal lymphadenopathy (Fig.1). Bronchoscopic examination revealed a hyperemic endobronchial tumor at the left apical-posterior segment and yielded a diagnosis of squamous cell carcinoma. The patient also had a history of coronary artery disease (CAD). Cardiac catheterization demonstrated 60% stenosis of the left main coronary artery, total occlusion of the left anterior descending coronary artery, and 60% stenosis of the right coronary artery (Fig. 2). After a cautious evaluation, minimally invasive surgery was performed. Following general anesthesia, a double-lumen endotracheal intubation was performed. The patient was placed in a supine position, and transesophageal echocardiographic monitoring was established. Subsequently, a left parasternal minithoracotomy was performed and the costal cartilages of the third and fourth rib were resected.<sup>(3)</sup> The left internal thoracic artery (LITA) was identified beside the sternal border and was mobilized from the first to the fifth intercostal space. Then the left internal thoracic artery and a great saphenous vein were harvested for the CABG procedure. Cardiopulmonary bypass (CPB) with systemic hypothermia (rectal tempera-

ture 25°C) was established through cannulation of the ascending aorta, and right atrium.

Proximal anastomosis of the saphenous vein graft to the ascending aorta was performed under direct vision. A double-lumen aortic root cannula (DPL, Grand Rapids, MI, USA) was then inserted at the aortic root for delivery of cardioplegic solution and venting of the left ventricle. A membranous oxygenator (Maxima Plus oxygenation system, Medtronic, Anaheim, CA, USA) was used during CPB. The aorta was cross-clamped at the distal part of the ascending aorta. The myocardium was protected by cold blood cardioplegic solution, which was infused into the aortic root at this moment, and again after completion of each distal anastomosis. The saphenous vein graft was grafted to the posterior descending branch with a continuous suture under direct vision. The LITA graft was then anastomosed to the left anterior descending artery while re-warming was started. After all anastomoses were complete, warm blood cardioplegia was infused into the aortic root. The clamp on the internal thoracic arterial graft and the aortic crossclamp were then removed and sinus rhythm recovered spontaneously. Subsequently, CPB was terminated following re-warming.

After completion of the CABG procedure, an upper left lung lobectomy with lymph node dissection was performed for the lung cancer. The left

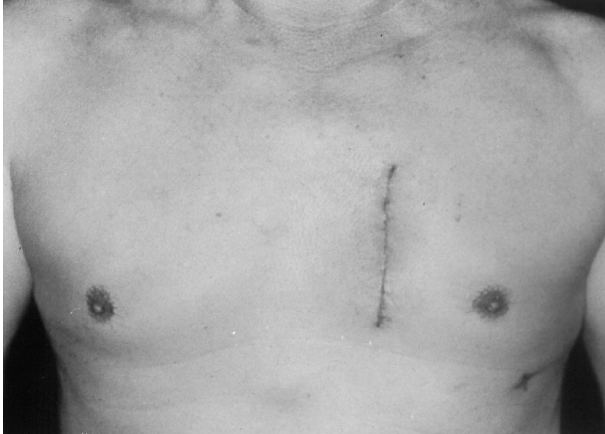lung was collapsed while the right lung was ventilated. The pulmonary ligament was divided to release the lung inferiorly and one 10-mm thoracoscope was inserted into the left thoracic cavity via the 7th intercostal space to facilitate posterior mediastinum exposure. The grafted LITA and the anastomosed saphenous vein graft were protected laterally from the operative field. The lung parenchyma was retracted with conventional lung forceps. Additionally, the interlobar arteries were identified and dissected, using a right-angled hemostat and diathermy. Sutures with 3-0 silks were applied to encircle the vessels and the ligation was performed similarly to an open thoracotomy. The pulmonary vein was managed identically to the interlobar artery. The interlobar bronchus was divided using an Endo-GIA stapler (Endoscopic linear cutter 45 mm, Ethicon Endo-Surgery, Cincinnati, OH). When the specimen was completely freed, it was retrieved and the lung was re-expanded to verify that the bronchial seal was adequate. Under video-assisted thoracoscopy, hilar lymph nodes dissection and mediastinal lymph node sampling were performed. One chest tube was placed, and the incision was closed in interrupted layers. Postoperatively, the remaining left lung expanded without evidence of air leak and the patient was discharged home uneventfully. Final pathology revealed a 3.2 cm moderately differentiated squamous cell carcinoma and negative mediastinal lymph node with a free bronchial margin, stage IB (T2N0). No complaints or clinical signs of recurrence were observed during the 6 month follow-up.

## DISCUSSION

Surgical treatment for patients with CAD and co-existing resectable lung cancer is usually staged with the revascularization procedure first, followed by the pulmonary resection at another time. However, this approach may delay tumor resection, increase costs and cause discomfort for the patient. Furthermore, tumor growth and dissemination can occur during the interval between the two procedures, which could worsen the prognosis. To resolve these problems, cardiovascular and thoracic surgeons have suggested simultaneous cardiac surgery with pulmonary resection as a safe and favorable survival procedure.<sup>(1,2)</sup> In general, there has been no major

difficulty with exposure for the pulmonary resection. Piehler et al. reported on 5 major pulmonary resections that were performed without difficulty during cardiopulmonary bypass suggested that careful hilar dissection and division of pulmonary fissures can be safely performed with the patient heparinized.<sup>(1)</sup> Therefore, in our institution, the decisions in a selected group of patients in whom concomitant procedures were performed usually were based on technical considerations. Simultaneous cardiac and pulmonary procedures are implied for patients without pleura adhesions or parietal tumor fixation recognized either preoperatively by roentgenographic studies or intraoperatively during the cardiac procedure. Patients in whom significant cardiac or pulmonary complications might be anticipated are not managed with concomitant operations.

Conventionally, long and painful surgical incisions, as well as malignant lung neoplasm resection are the standard approach for CABG. Empirical results from these conventional surgical procedures were acceptable. However, incisional pain, poor cosmetic effect, and mediastinitis occasionally occur. Technological advances in minimally invasive surgery have transformed general thoracic, cardiac, gynecological, and general, as well as orthopedic surgery. Videothoroscopic lobectomy and cardiac surgery have been proved feasible, with promising results.<sup>(4-6)</sup> Nevertheless, no case of coinstantaneous cardiac and thoracic surgery via a minimally invasive approach has been reported. Based on our previous experience with minimally invasive thoracic and cardiovascular surgery, simultaneous CABG and pulmonary operations were performed in a 65-year-old man with CAD associated with left upper lung cancer via a left parasternal minithoracotomy. The major advantages of left parasternal approach in CABG are the avoidance of sternotomy, adequate myocardial protection with cardioplegic arrest, and the ability to do multiple graftings for complete revascularization. Following CABG, the grafted LITA and anastomosed saphenous vein can be well protected laterally from the operative field while performing the pulmonary resection via the left parasternal approach. There is no question, however, that complete hilar and mediastinal dissections are more easily performed through a posterolateral thoracotomy. With video-assisted thoracoscopy, hilar dissec-



**Fig. 3** Good cosmetic healing of the left parasternal minithoracotomy incision

tions and mediastinal lymph nodes dissections can be performed without difficulty. Our previous experience with minimally invasive thoracic and cardiovascular surgery indicates that it is expedient and safe with minimal discomfort, less postoperative pain, quick functional recuperation, excellent cosmetic healing, and shortened hospital stays, thereby decreasing costs (Fig. 3).<sup>(3,7-9)</sup> Hence, a minimal access approach to perform concomitant CAD and resectable lung cancer was attempted. The major advantages of concomitant operation via a minimally invasive approach include omitting the sternotomy and posterolateral thoracotomy, without compromise of essential procedures and adequate results. Thus, a minimally invasive procedure per se can reduce the incidence of postoperative mediastinitis and decrease wound pain.<sup>(10)</sup> One limitation of the left parasternal approach is poor exposure for pulmonary resection in patients with CAD with right lung cancer.

Using endoscopic instruments manipulated through trocars or thoracoports often complicates the procedure and is time-consuming, especially when major procedures such as CABG or lobectomy are performed. Hence, for a safer, quicker, and more

economical procedure, the importance of using conventional instruments under video-assisted thoracoscopy when performing major cardiac and thoracic procedures via the minimally invasive approach is emphasized. The promising results of a minimally invasive approach demonstrated the technical feasibility of concomitant surgery for a triple vessel disease and lung cancer.

## REFERENCES

1. Piehler JM, Trastek VF, Pairolero PC, Pluth JR, Danielson GK, Schaff HV, Orszulak TA, Puga FJ. Concomitant cardiac and pulmonary operations. *J Thorac Cardiovasc Surg* 1985;90:662-7.
2. Canver CC, Bhayana JN, Lajos TZ, Raza ST, Lewin AN, Bergsland J, Mentzer RM Jr. Pulmonary resection combined with cardiac operations. *Ann Thorac Surg* 1990;50:796-9.
3. Wu YC, Chang CH, Lin PJ, Chu JJ, Tsai FC, Yang MW, Tan PC. Minimally invasive approach for coronary artery bypass surgery. *Int J Cardio* 1997;62(Suppl 1):S111-7.
4. Lewis RJ, Sisler GE, Caccavale RJ. Imaged thoracic lobectomy: should it be done? *Ann Thorac Surg* 1992; 54:80-3.
5. Roviato G, Rebuffat C, Varoli F, Vergnic C, Mariani C, Maciocco M. Video-endoscopic pulmonary lobectomy for cancer. *Surg Laparosc Endosc* 1992;2:244-7.
6. Walker WS, Carnochan FM, Pugh GC. Thoracoscopic pulmonary lobectomy: early operative experience and preliminary clinical results. *J Thorac Cardiovasc Surg* 1993;106:1111-7.
7. Liu HP, Chang CH, Lin PJ, Hsieh HC, Chang JP, Hsieh MJ. Video-assisted thoracic surgery: the Chang Gung experience. *J Thorac Cardiovasc Surg* 1994;108:834-40.
8. Wu YC, Chang CH, Lin PJ, Chu JJ, Liu HP, Yang MW, Hsieh HC, Tsai FC. Minimally invasive cardiac surgery for intracardiac congenital lesions. *Eur J Cardiothorac Surg* 1998;14(Suppl):154-9.
9. Chang YS, Lin PJ, Chang CH, Chu JJ, Tan PP. "I" ministernotomy for aortic valve replacement. *Ann Thorac Surg* 1999;68:40-5.
10. Magovern JA, Mack MJ, Landreneau RJ, Acuff TE, Benckart DH, Hunter TJ, Magovern GJ. The minimally invasive approach reduces the morbidity of coronary artery bypass. *Circulation* 1996;94(Suppl I):I-52.

## 冠狀動脈狹窄合併肺癌之微創手術治療

呂宏益 吳怡成 謝明儒 劉會平 林萍章

傳統上針對冠狀動脈狹窄病患同時合併肺癌的治療方式，大部分採取分階段手術，先施行經正中胸骨切開之冠狀動脈繞道手術，一段時間後再側臥開胸作肺部腫瘤的切除。然而此種治療方式除了延遲肺癌切除的時機外，分成兩次手術亦增加術後的併發症及醫療成本。因此開始有人嘗試同時合併施行開心及開胸手術，並且成功地克服體外循環對合併手術的影響。由過去在微創開心及開胸手術的經驗，我們進一步利用單一微創切口同時完成冠狀動脈繞道手術及肺癌切除手術。本文報告一例65歲男性冠狀動脈狹窄病患同時發現左上肺鱗狀細胞癌，成功地經由左側胸骨旁微創切口，順利施行冠狀動脈繞道手術及左上肺葉切除手術，術後追蹤六個月沒有復發及臨床症狀。由此經驗我們想要強調，經由微創切口，施行冠狀動脈繞道手術合併肺癌切除應是一種可行且安全的治療方式。(長庚醫誌 2002;25:110-4)

**關鍵字：**微創手術，冠狀動脈狹窄，肺癌。